

ORIGINAL ARTICLE

Long-term follow-up after endovascular treatment of hepatic venous outflow obstruction following liver transplantation

Maheswaran Pitchaimuthu¹, Garrett R. Roll^{1,2}, Zergham Zia³, Simon Olliff³, Homoyoon Mehrzad³, James Hodson⁴, Bridget K. Gunson⁴, M. Thamara P. R. Perera¹, John R. Isaac¹, Paolo Muiasan¹, Darius F. Mirza^{1,4} & Hynek Mergental^{1,4}

1 Liver Unit Queen Elizabeth Hospital, University Hospitals Birmingham NHS Foundation Trust, Birmingham, UK

2 Division of Transplant Surgery, University of California, San Francisco, CA, USA

3 Department of Radiology, Queen Elizabeth Hospital, University Hospitals Birmingham NHS Foundation Trust, Birmingham, UK

4 National Institute for Health Research Birmingham, Liver Biomedical Research Unit and Centre for Liver Research, Institute of Immunology and Immunotherapy, College of Medical and Dental Sciences, University of Birmingham, Birmingham, UK

Correspondence

Mr. Hynek Mergental MD, PhD, Liver Unit, Queen Elizabeth Hospital, University Hospitals Birmingham NHS Foundation Trust, Birmingham B15 2TH, UK.

Tel.: +44 121 371 4638;

fax: +44 121 414 1833;

e-mail: hynek.mergental@uhb.nhs.uk

SUMMARY

Hepatic venous outflow obstruction (HVOO) is a rare complication after liver transplantation (LT) associated with significant morbidity and reduced graft survival. Endovascular intervention has become the first-line treatment for HVOO, but data on long-term outcomes are lacking. We have analysed outcomes after endovascular intervention for HVOO in 905 consecutive patients who received 965 full-size LT at our unit from January 2007 to June 2014. There were 27 (3%) patients who underwent hepatic venogram for suspected HVOO, with persistent ascites being the most common symptom triggering the investigation ($n = 19$, 70%). Of those, only 10 patients demonstrated either stricture or pressure gradient over 10 mmHg on venogram, which represents a 1% incidence of HVOO. The endovascular interventions were balloon dilatation ($n = 3$), hepatic vein stenting ($n = 4$) and stenting with dilatation ($n = 3$). Two patients required restenting due to stent migration. The symptoms of HVOO completely resolved in all but one patient, with a median follow-up period of 74 (interquartile range 39–89) months. There were no procedure-related complications or mortality. In conclusion, the incidence of HVOO in patients receiving full-size LT is currently very low. Endovascular intervention is an effective and safe procedure providing symptom relief with long-lasting primary patency.

Transplant International 2016; 29: 1106–1116

Key words

hepatic vein stent, hepatic venogram, hepatic venoplasty, hepatic venous outflow obstruction, liver transplantation, piggyback technique

Received: 27 January 2016; Revision requested: 7 March 2016; Accepted: 28 June 2016; EV Pub Online: 13 September 2016

Introduction

Liver transplantation (LT) is the treatment of choice for patients with end-stage chronic liver disease, early stages of liver cancer and fulminant hepatic failure. Over the

past 4 decades, the surgical technique has evolved significantly, with a concomitant fall in morbidity and mortality [1]. Initially, LTs were performed using caval replacement, but this was associated with hemodynamic instability [2,3]. Calne and Williams first introduced

caval preservation in 1968, and this was reintroduced 20 years later and termed ‘piggyback’ technique and has gained widespread acceptance [4–6].

Hepatic venous outflow obstruction (HVOO), so-called piggyback syndrome, is a rare but potentially lethal complication after LT [7–10]. HVOO is more commonly associated with use of partial liver grafts, with a reported incidence between 1.5% and 4% compared to a rate of 1% after full-size LT [11–15]. HVOO can occur in the early postoperative period, possibly from direct compression of the hepatic veins, but can also occur several months to years later from fibrotic changes at the anastomosis [16–18].

Hepatic venous stenosis presents with ascites, variceal haemorrhage, splenomegaly and abnormal liver and kidney function [19]. Early detection of HVOO is important as the liver graft dysfunction can result from congestion, and timely intervention such as balloon angioplasty or stent placement can preserve graft function [11,20–23]. Long-term follow-up data after endovascular treatment for HVOO are lacking. We present the long-term follow-up of our experience with management of HVOO in a large single centre series.

Patients and methods

Study design and patients

Retrospective analysis of a prospectively maintained database of patients who had liver transplantation at the Liver Unit in Birmingham between 1 January 2007 and 30 June 2014 was performed. The start of the study period coincided with the transition from film-based to digital-based imaging in our radiology department.

There were a total of 1086 liver transplant procedures performed on 1026 patients. One hundred and twenty-one procedures were performed with partial grafts (116 right lobe grafts and 5 left lobe grafts, including 7 live donor liver transplants). These patients were excluded from the study. Nine hundred and five patients who received full-size liver grafts were included in our study. From this cohort, we identified patients who developed symptoms suspicious of HVOO and collected their demographic details, indication for liver transplantation, clinical presentation of suspected HVOO, venograms and details of endovascular interventions. Data regarding symptom relief were collected during clinic follow-up appointments and the date of last follow-up in this study was 31 March 2016. A range of donor- and organ-related factors were compared between those patients that did and did not develop HVOO. Overall

patient and graft survival and survival with and without HVOO were compared.

The primary study endpoints were resolution of symptoms and post-transplant survival. Any stent-related complications were recorded according to Clavien-Dindo classification [24]. The procedure-related death was defined as any mortality within 90 days following the intervention.

Surgical technique of the hepatic venous outflow reconstruction

Liver transplants were performed by a team of eight transplant surgeons using piggyback technique. The unit changed from the inferior vena cava (IVC) replacement to piggyback implantation technique in 2000. The technical detail of the piggyback technique and its modifications are shown in Fig. 1. Six surgeons performed modified piggyback implantation as popularized by Belghiti, with both ends of the IVC closed and large side-to-side caval anastomosis (variant 1) [5]. One surgeon each performed side-to-side cavocavostomy with upper open end of the IVC included in the anastomosis (variant 2) and classical technique creating anastomosis between the suprahepatic part of the donor IVC and the common orifice of left and middle hepatic veins (variant 3) [25]. With all approaches, the native IVC flow was maintained throughout the implantation period.

The anastomosis was performed with a continuous, nonabsorbable polypropylene 4-0 suture (Prolene; Ethicon Inc., Livingston, UK). In the case of the longitudinal cavocavostomy, the recipient IVC venotomy was performed as close to the diaphragm as technically feasible, usually placing the upper corner of the anastomosis above the level of the native hepatic veins (Fig. 2). For the side-to-side technique, with both ends of the donor IVC closed, the graft venotomy was positioned as close to the suprahepatic IVC suture line as possible.

Post-transplant immunosuppression and follow-up

Post-transplant immunosuppression consisted of tacrolimus-based therapy in combination with either azathioprine or mycophenolate mofetil, and a 3-month course of prednisolone. All patients received aspirin 75 mg daily as standard long-term prophylaxis of hepatic artery thrombosis.

After discharge from hospital, patients were followed up on a weekly (first 6 weeks) then fortnightly (after 6 weeks) basis until 3 months after transplantation.

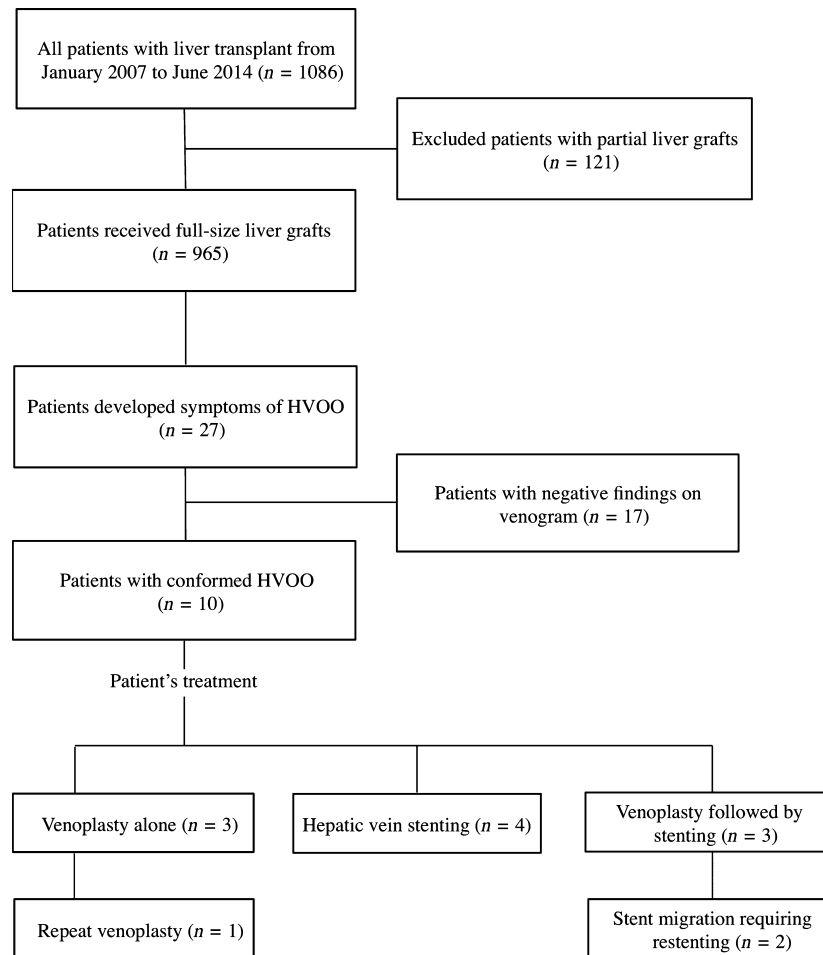


Figure 1 Study inclusion flow chart.

Each outpatient consultation consisted of a clinical review and blood analysis including liver function tests.

Hepatic venous outflow obstruction diagnosis and interventions

The clinical symptoms triggering the suspicion of HVOO were persistent ascites, lower extremity oedema,

pleural effusion and deranged liver function. All patients with any of those symptoms underwent Doppler liver ultrasound and subsequently hepatic venography, performed through transjugular approach in all patients. All patients diagnosed with HVOO on hepatic venography (slow flow across the anastomosis, pressure gradient greater than 10 mmHg across the anastomosis and stenosis at the anastomosis) were treated with

Figure 2 Technical aspects and variants of the piggyback anastomosis. The figure highlights technical aspects of the piggyback hepatic venous outflow reconstruction. (Panel a) Demonstrates back-table preparation of the graft inferior vena cava (IVC) with the divided retrocaval ligament, exposing the posterior aspect of the retrohepatic IVC; this preparation is not necessary for the conventional piggyback technique (see below). (Panel b) Shows the incision in the posterior aspect of the suprahepatic IVC and orifices of all the three hepatic veins. (Panel c) Displays the recipient IVC after the native liver hepatectomy, the stump of the right hepatic vein divided with an endo-GIA vascular stapler in the longitudinal direction and the stump of the left and middle hepatic veins in the transverse direction close to the diaphragm. (Panel d) Illustrates the Babcock clamps used to apply traction on the anterior aspect of the IVC wall to facilitate placement of a large Satinsky clamp as demonstrated in (Panel e), preserving approximately 50% of the vascular flow. (Panel f) Displays the longitudinal venotomy with placed stay sutures in preparation for the side-to-side venoplasty. (Panel g) Shows a suture in the inferior and (Panel h) a suture in the superior corners of the donor IVC. (Panel i) Demonstrates the sutured right side of the caval anastomosis. (Panel j) Shows the right-side lateral view of the implanted liver graft. (Panel k) Shows the recipient IVC opening used to perform side-to-side modified (left) or end-to-side traditional piggyback anastomosis. (Panel l) Displays the lateral view of the postimplantation anatomical situation in variants 1 (top) and 2 (middle) of side-to-side cavostomy; the bottom drawing shows traditional piggyback anastomosis of the donor suprahepatic IVC to the orifices of the left and middle hepatic veins.

venoplasty with 10- to 12-mm balloon initially. If the pressure gradient was persistently high and/or residual stenosis was present even after venoplasty on check

venogram, then they were treated with a 10- to 12-mm self-expanding uncovered stent (Boston Scientific Vascular Wallstent) during the index procedure.

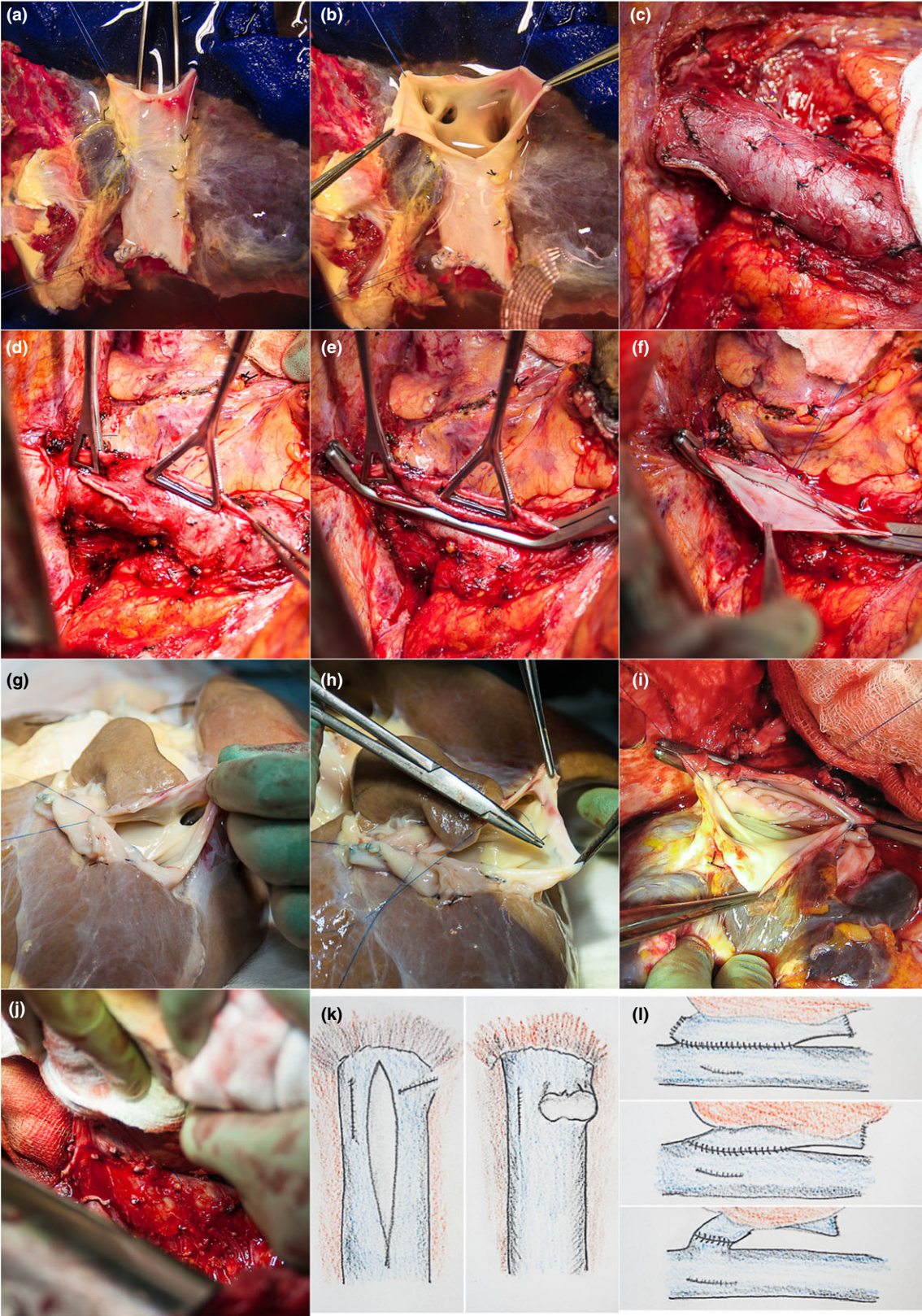


Table 1. Recipient indication for liver transplantation.

| | All patients (<i>n</i> = 965) | Patients with suspected HVOO (<i>n</i> = 27) | Patients with proven HVOO (<i>n</i> = 10) |
|----------------------------------|-----------------------------------|--|---|
| Fulminant hepatic failure* | 100 | 4 | 2 |
| Hepatocellular carcinoma† | 164 | 1 | 2 |
| Hepatitis C Virus | 91 | 3 | 0 |
| Primary biliary cirrhosis | 102 | 3 | 0 |
| Primary sclerosing cholangitis | 89 | 2 | 1 |
| Alcohol-related liver disease | 150 | 2 | 1 |
| Autoimmune hepatitis | 25 | 2 | 1 |
| Budd–Chiari Syndrome | 8 | 2 | 1 |
| Alpha-1 antitrypsin deficiency | 13 | 2 | 1 |
| Nonalcoholic steatohepatitis | 40 | 2 | 0 |
| Nodular regenerative hyperplasia | 12 | 1 | 0 |
| Polycystic liver disease | 20 | 1 | 0 |
| Cryptogenic cirrhosis | 22 | 1 | 0 |
| Retransplantation† | 60 | 1 | 1 |
| Others | 69 | 0 | 0 |

HVOO, hepatic venous outflow obstruction.

*Indication included fulminant liver failure caused by paracetamol overdose, seronegative and drug-induced hepatitis.

†Various aetiology or indication.

Patients who had persistent symptoms postprocedure were subjected to repeat venogram. Again during the second venogram, venoplasty was initially attempted, but patients with high pressure gradient and/or residual stenosis after venoplasty were stented. Two experienced interventional liver radiologists performed all interventions and the findings were discussed at a multidisciplinary liver transplant meeting. Patients who had no evidence of HVOO on hepatic venography were treated with diuretics rather than endovascular therapy.

Statistical analysis

Continuous variables were presented as median with interquartile range and the categorical variables were presented as numbers and percentages. Survival was calculated using Kaplan–Meier method. Univariate analysis was performed to assess the relationship between HVOO and various donor- and graft-related factors. SPSS software (version 22.0; SPSS Inc., Chicago, IL, USA) was used to perform statistical analysis. For presenting the results, percentages were rounded to whole numbers and *p*-values to three decimals.

Results

A total of 905 patients received 965 full-size graft transplants over the study period. Among these, 60 were

retransplantations for various indications, but none of the retransplants were performed for HVOO. Only 27 (3%) patients developed symptoms suggestive of HVOO. These cases constituted the presented series cohort and are shown in Table 1. Caval anastomosis was performed as variant 1 in 751, variant 2 in 97 and variant 3 in 117 patients (Fig 2.). Among the symptomatic patients, twenty-six patients had caval reconstruction with side-to-side cavostomy (variant 1) and one patient had the donor suprahepatic IVC reconstruction to the recipient left and middle hepatic veins (variant 3; this patient did not have proven HVOO on venogram) (Table 2).

The median time between transplantation and development of symptoms suggestive of HVOO was 3 [interquartile range (IQR) 1.7–6.9] months, with the overall follow-up period of 101 months. The most common presenting symptom was ascites (*n* = 19, 70%). Other symptoms suggestive of HVOO were deranged liver function (*n* = 5), lower extremity oedema (*n* = 5), pleural effusion (*n* = 3) and two patients had evidence of venous congestion on liver biopsy. These symptomatic patients underwent percutaneous hepatic venogram with pressure measurements in right atrium, IVC and hepatic veins. Ultrasound findings suggestive of HVOO (disappearance of pulsatile hepatic venous outflow or flattening of the hepatic venous waves) were present only in 4 of our 27 (15%) patients. Liver biopsy findings of HVOO were congestion, haemorrhage and

Table 2. Patient and graft survival.

| | All patients (<i>n</i> = 965) | Patients with suspected HVOO (<i>n</i> = 27) | Patients with proven HVOO (<i>n</i> = 10) |
|-----------------------------------|-----------------------------------|--|---|
| Piggyback surgical reconstruction | | | |
| Variant 1 | 751 | 26 | 10 |
| Variant 2 | 97 | 0 | 0 |
| Variant 3 | 117 | 1 | 0 |
| 1-year graft survival | 86% | 100% | 100% |
| 5-year graft survival | 76% | 82% | 70% |
| 1-year patient survival | 90% | 100% | 100% |
| 5-year patient survival | 79% | 87% | 80% |

HVOO, hepatic venous outflow obstruction.

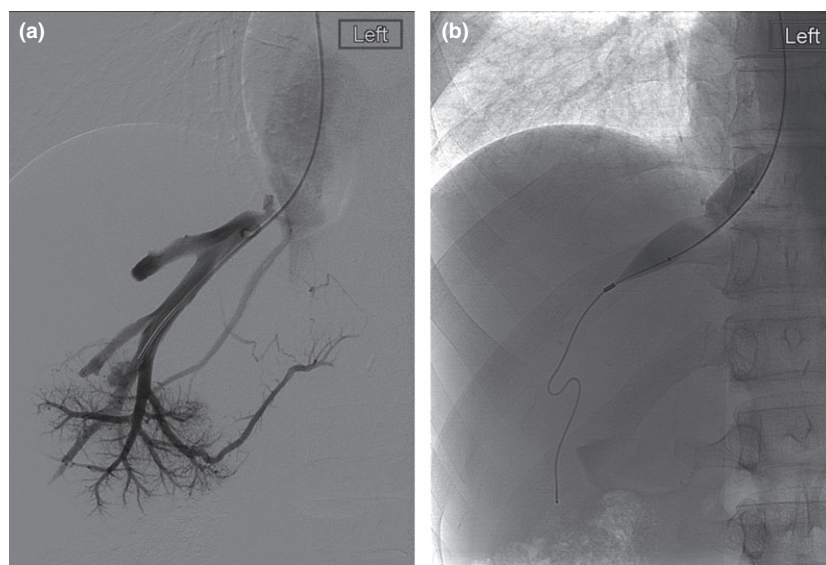


Figure 3 Venogram of a patient with hepatic venous outflow obstruction. Hepatic venogram shows narrowing at the anastomosis level (Panel a) treated with balloon venoplasty demonstrates resolved stenosis (Panel b).

necrosis around the central veins, and were present in two patients (7%). Only 10 of the 27 (37%) patients with symptoms concerning for HVOO had a hepatic venous pressure gradient greater than 10 mmHg or venogram suggestive of stricture and all these patients had side-to-side cavocavostomy anastomosis. This yields an overall incidence of HVOO in our series of 1.1%.

Among the 10 patients with positive venogram, three patients who had high pressure gradient or stenosis at the anastomosis were treated only with hepatic venoplasty (Fig. 3). Four patients with persistent high pressure gradient, even after venoplasty on check venogram, were treated with hepatic venous stenting during the index venogram (Fig. 4). Three patients were treated initially with hepatic venoplasty, but, due to persistent

symptoms and pressure gradient/residual stenosis on a subsequent venogram even after repeat venoplasty, they underwent hepatic vein stenting. In all patients, pressure gradient of <10 mmHg and/or disappearance of stenosis was confirmed with postvenoplasty/stenting venograms. The median post-transplant and postprocedure follow-up periods were 76 (IQR 54–91) months and 74 (IQR 39–89) months, respectively.

In all patients in the intervention group, the symptoms of HVOO resolved completely. Of two patients in this group who had deranged liver function tests along with other symptoms of HVOO before the procedure, 1 had stenting and the liver function became normal during follow-up, and one patient had hepatic venoplasty and was scheduled to undergo stenting, but was lost to

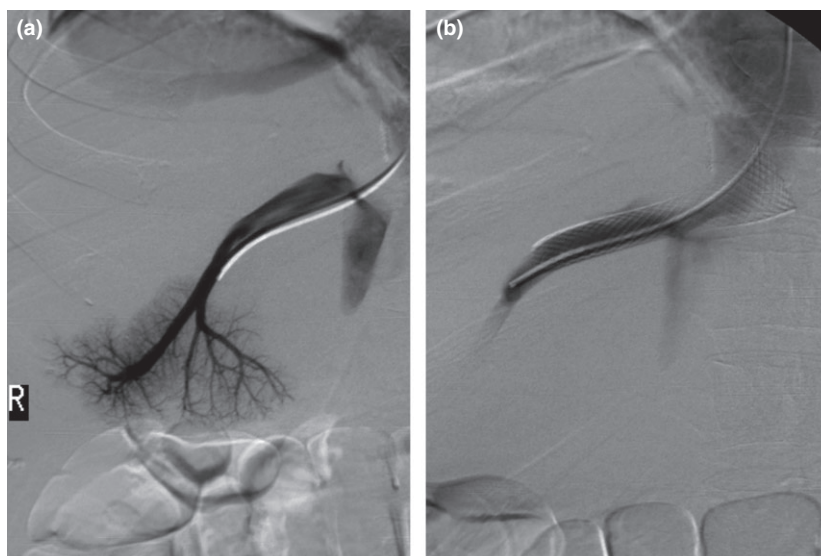


Figure 4 Venogram of a patient undergoing hepatic venous outflow stenting. The figure shows hepatic venogram with narrowing at the anastomosis level prior (Panel a) and after (Panel b) the stent insertion.

Table 3. Risk factors for hepatic venous outflow obstruction.

| | HVOO | | <i>P</i> -value |
|--------------------------------------|----------------------|----------------------|-----------------|
| | No (<i>n</i> = 895) | Yes (<i>n</i> = 10) | |
| Donor age (years) | 50 ± 15 | 50 ± 15 | 1.000 |
| Donor height (cm) | 169 ± 11 | 171 ± 10 | 0.523 |
| Donor weight (kg) | 75 ± 15 | 79 ± 10 | 0.441 |
| Body mass index (kg/m ²) | 26 ± 5 | 27 ± 4 | 0.644 |
| Cold ischaemic time (min) | 487 ± 135 | 555 ± 117 | 0.113 |
| Steatosis | 75 (8%) | 1 (10%) | 0.586 |
| Suboptimal organ | 283 (32%) | 1 (10%) | 0.185 |

HVOO, hepatic venous outflow obstruction.

Data reported as mean ± standard deviation with *P*-values from *t*-tests, or *N* (%) with *P*-value from Fisher's exact test, as applicable. This analysis includes only 905 patients who received primary transplant with full-size graft.

follow-up due to noncompliance and this patient died 28 weeks later from opioid overdose and noncompliance with immunosuppression.

During follow-up, two patients were found to have stent migration, requiring restenting, and one patient had repeated balloon dilatation for persistent ascites (Fig. 4). There was no procedure-related mortality in our series. Of the patients who underwent intervention for HVOO, two patients died during follow-up from causes unrelated to HVOO (meningioma and chronic rejection after a 4th LT).

Of the 17 patients with symptoms of HVOO but no HV pressure gradient or venogram findings suggestive of HVOO (and therefore no intervention performed), two patients died. One of these patients died from

squamous cell carcinoma of the ear and the other from hepatitis C recurrence.

On univariate analysis, donor-related factors (donor age, height, weight and BMI) and graft-related factors (cold ischaemic time, graft steatosis, surgeons' pretransplant assessment about the graft) were analysed between patients with and without HVOO. None of these comparisons were found to be significant (Table 3). However, due to the small sample size in the HVOO group, the statistical power of this analysis was low. Overall patient survival and graft survival were calculated for the whole study period. Patient survival and graft survival were compared separately for patients with and without HVOO. (Table 2 and Fig. 5).

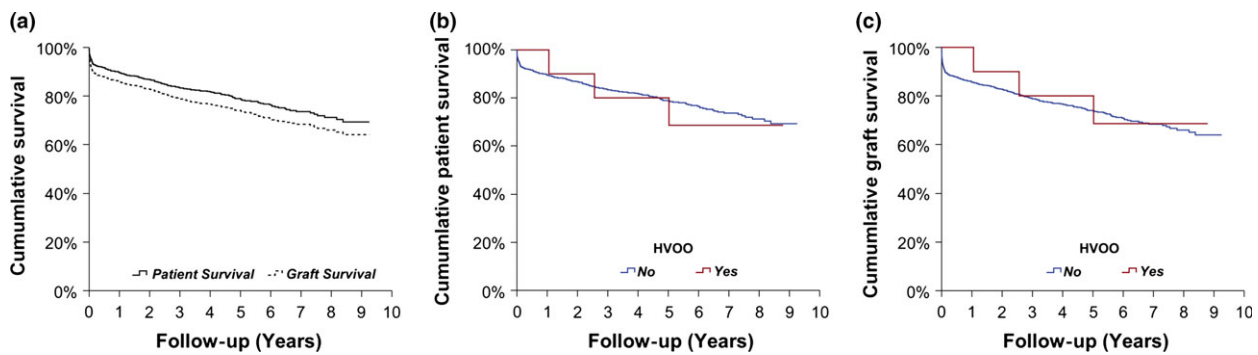


Figure 5 Patient and graft survival. (Panel a) Demonstrates the Kaplan–Meier curves with the overall patient (full line) and graft (dotted line) survivals of all 965 full-size liver transplant recipients transplanted over the study period. (Panel b) Shows the overall survival of patients without (blue line), respective with proven (red line) hepatic venous outflow obstruction. (c) Shows the graft survival in the same groups of patients.

Discussion

Hepatic venous outflow obstruction due to anastomotic stricture is a very rare complication after liver transplantation in adult recipients who receive full-size liver grafts in a piggyback technique [26]. HVOO early after liver transplantation is associated with high morbidity and mortality; almost one-third of patients will require retransplantation if surgical and endovascular interventions fail [27,28]. HVOO occurring in the early postoperative period is thought to be secondary to several factors, such as a tight suture line, kinking of a redundant hepatic vein, donor–recipient size discrepancy or caval compression from a large graft [14]. HVOO occurring after the first 3 months is thought to arise from fibrosis of the anastomotic site and intimal hyperplasia [14]. Vilca *et al.* [29] reported that caval replacement technique has the advantages of wider retrohepatic cava which avoids venous outflow or caval obstruction.

The existing literature describes an incidence of HVOO after full-size graft liver transplantation between 0.8% and 1% concurrent with our incidence of 1% [22,28]. It is well documented that the incidence of HVOO is higher in patients receiving partial liver grafts, ranging between 3.9% and 16.6% [13,21,23,30]. This is likely due to the fact that the anastomosis of the hepatic veins to the IVC in partial grafts is smaller [31,32]. Additionally, partial liver grafts usually grow considerably after transplantation, so the hepatic venous outlet might be compromised by distortion of the outlet [26,33].

Patients with hepatic venous outflow obstruction usually present with large volume ascites, which is refractory to diuretic therapy and protein supplementation, and bilateral lower limb oedema [22,28]. Clinically

significant early post-transplant HVOO usually causes deterioration of liver and renal function. In some patients, HVOO can also cause symptoms including ascites and renal dysfunction without deterioration of hepatic function [34]. In either case, early treatment of HVOO is critical to prevent morbidity and mortality [35–37].

In our series, the most commonly described symptom was ascites, present in 76% of our patients with suspected HVOO, but 27% of patients with a positive venogram. Deranged liver function, lower extremity oedema and pleural effusions are some of the other symptoms in our series. In two patients, liver biopsy demonstrated evidence of hepatic venous congestion, leading to an eventual diagnosis of HVOO.

Doppler ultrasound is a useful screening test in patients suspected of having HVOO, when a dampened waveform with decreased mean velocity in the hepatic veins is seen [38]. If significant stenosis develops, the waveform usually degrades to a monophasic pattern, and in some cases reversal of flow in the hepatic veins can be demonstrated [39–41]. Reduced pulsatility is associated with transplant hepatic vein stenosis [42]. The venous pulsatility index, described by Coulden *et al.* and Chong *et al.* [43,44], can be used to increase the specificity of Doppler ultrasound.

Venography and measurement of pressures within the hepatic veins is the confirmatory test of choice in patients suspected of having HVOO [19,45]. There is no consensus on the hepatic vein pressure gradient that is significant in a patient suspected of having HVOO, and pressure gradients from 3 to 20 mmHg have been reported as the threshold of clinical significance [40]. A gradient greater than 10 mmHg between the hepatic vein and the right atrium is most commonly used for the diagnosis of HVOO [11,46]. In our study, the

presence of HVOO symptoms with a gradient of 10 mmHg and/or stricture on venogram was an indication for intervention.

Therapeutic options for HVOO include angioplasty with or without stent placement, surgical reconstruction of the venous anastomosis and retransplantation [47]. Hepatic venous outflow obstruction immediately after transplantation can be treated with surgical revision of the HV anastomosis [23,47,48]. Conversely, late-onset hepatic venous outflow obstruction produces insidious deterioration of liver and kidney function, and surgical correction is difficult; thus, endovascular interventions are preferred [15,49–52].

In our series, there were no patients with early HVOO requiring reoperation or retransplantation. The median duration between liver transplantation and the development of symptoms requiring venogram was 3 months. This was considered late-onset HVOO and was treated with venoplasty and/or stenting.

Ten of the 27 patients with suspected HVOO had a pressure gradient over 10 mmHg and/or stricture at the anastomosis. All of these patients were initially treated with balloon dilatation, unless there was a persistent high pressure gradient on the check venogram. In such cases, a stent was placed during the index venogram ($n = 4$). Hypotension, arrhythmia, stent occlusion, restenosis and stent migration are some reported complications of hepatic vein stents [33]. In our study, two out of seven patients who were stented developed stent migration requiring a second stent. None of our patients developed a procedure-related complication. Symptoms resolved in all treated patients, except the patient who did not attend the appointment for stent placement.

Repeated balloon dilatation or stent placement after the venoplasty may be required for persistent symptoms of HVOO and high pressure gradient or recurrent stenosis. In our study, one patient required a second balloon dilatation, and three patients required stenting after dilatation. For refractory cases, formal reconstruction of outflow may be required. Quintini *et al.* [47] suggested a side-to-side cavostomy using GIA stapler. There was no need for any surgical intervention in our patients for HVOO.

The literature describing the management of HVOO after full-size graft liver transplantation is dominated by case reports [53]. Most of the available literature on HVOO is from experiences in living donor transplantation [33]. Quintela *et al.* [31] reported their experience with end-to-side cavocavostomy for early hepatic venous outflow obstruction with 45-month follow-up, but there are no reports of long-term follow-up after

endovascular intervention. With the median follow-up of 74 months and maximum overall follow-up of 101 months, none of our patients required surgical intervention for HVOO, indicating that the combination of balloon angioplasty and/or stenting has long-term success in the management of HVOO.

On further analysis, no risk factors have been identified that may be related to development of this complication. In accordance with previous reports, we observed perhaps more cases with HVOO in patients transplanted for Budd–Chiari syndrome [54,55]. The relatively higher incidence in patients undergoing liver retransplantation might be explained by the technical aspects of the challenging procedure, with possible kinking or twisting of the IVC anastomosis, performed usually on the IVC cuff remaining from the failed graft. For the recipients with fulminant liver failure, we can speculate that HVOO might be related to cases when the procedure urgency might have led to usage of size-mismatched organs, with a relatively large graft compressing the venous outflow. It would be interesting to perform prospective analyses to detect factors associated with HVOO, which could be used to identify patients at risk of the complication. The inability to perform this represents a limitation of this report, but due to the infrequency of HVOO occurrence, this would require a large, multicentre transplant registry study to collect a sufficient sample size to attain adequate statistical power for the detection of clinically relevant associations.

We conclude that the incidence of HVOO in patients receiving full-size liver transplantation is 1%. Endovascular intervention is effective with negligible procedure-related morbidity. The median follow-up period of 74 months after treatment demonstrates that endovascular treatments provide symptom relief with long-lasting primary patency, with only three patients requiring repeated interventions.

Authorship

MP and HM: initiated the study. MP and BKG: collected the data. JH and MP: performed the statistical analysis. MP, ZZ, GRR and HM: were responsible for the study management, data interpretation, manuscript preparation and submission. SO, ZZ and HoM: performed the diagnostic and therapeutic radiological interventions. MTPR, JRI, PM, DFM and HM: were involved in the transplantation procedures and post-transplant patient management. All co-authors actively contributed to the article drafting and approved the final manuscript.

Funding

The investigators did not receive any financial support for this study.

Conflicts of interest

The authors have declared no conflicts of interest.

REFERENCES

- Mehrabi A, Fonouni H, Muller SA, Schmidt J. Current concepts in transplant surgery: liver transplantation today. *Langenbecks Arch Surg* 2008; **393**: 245.
- Schmidt J, Muller SA, Mehrabi A, Schemmer P, Buchler MW. [Orthotopic liver transplantation. Techniques and results]. *Chirurg* 2008; **79**: 112.
- Estrin JA, Belani KG, Ascher NL, Lura D, Payne W, Najarian JS. Hemodynamic changes on clamping and unclamping of major vessels during liver transplantation. *Transplant Proc* 1989; **21**: 3500.
- Calne RY, Williams R. Liver transplantation in man. I. Observations on technique and organization in five cases. *Br Med J* 1968; **4**: 535.
- Tzakis A, Todo S, Starzl TE. Orthotopic liver transplantation with preservation of the inferior vena cava. *Ann Surg* 1989; **210**: 649.
- Ming YZ, Niu Y, Shao MJ, She XG, Ye QF. Hepatic veins anatomy and piggyback liver transplantation. *Hepatobiliary Pancreat Dis Int* 2012; **11**: 429.
- Koneru B, Tzakis AG, Bowman J 3rd, Cassavilla A, Zajko AB, Starzl TE. Postoperative surgical complications. *Gastroenterol Clin North Am* 1988; **17**: 71.
- Lerut J, Gordon RD, Iwatsuki S, Starzl TE. Surgical complications in human orthotopic liver transplantation. *Acta Chir Belg* 1987; **87**: 193.
- Lerut J, Tzakis AG, Bron K, et al. Complications of venous reconstruction in human orthotopic liver transplantation. *Ann Surg* 1987; **205**: 404.
- Orons PD, Zajko AB. Angiography and interventional procedures in liver transplantation. *Radiol Clin North Am* 1995; **33**: 541.
- Ko GY, Sung KB, Yoon HK, et al. Endovascular treatment of hepatic venous outflow obstruction after living-donor liver transplantation. *J Vasc Interv Radiol* 2002; **13**: 591.
- Choi JW, Jae HJ, Kim H-C, et al. Long-term outcome of endovascular intervention in hepatic venous outflow obstruction following pediatric liver transplantation. *Liver Transpl* 2015; **21**: 1219.
- Emond JC, Heffron TG, Whittington PF, Broelsch CE. Reconstruction of the hepatic vein in reduced size hepatic transplantation. *Surg Gynecol Obstet* 1993; **176**: 11.
- Fujimoto M, Moriyasu F, Someda H, et al. Recovery of graft circulation following percutaneous transluminal angioplasty for stenotic venous complications in pediatric liver transplantation: assessment with Doppler ultrasound. *Transpl Int* 1995; **8**: 119.
- Harihara Y, Makuuchi M, Takayama T, et al. Venoplasty of recipient hepatic veins in living-related liver transplantation. *Transplant Proc* 1998; **30**: 3205.
- Buell JF, Funaki B, Cronin DC, et al. Long-term venous complications after full-size and segmental pediatric liver transplantation. *Ann Surg* 2002; **236**: 658.
- Wang SL, Sze DY, Busque S, et al. Treatment of hepatic venous outflow obstruction after piggyback liver transplantation. *Radiology* 2005; **236**: 352.
- Sieders E, Peeters PM, TenVergert EM, et al. Early vascular complications after pediatric liver transplantation. *Liver Transpl* 2000; **6**: 326.
- Liu XL, Li FQ, Li X, Li B, Yan LN, Wei YG. Treatment of hepatic venous outflow stenosis after living donor liver transplantation by insertion of an expandable metallic stent. *Hepatobiliary Pancreat Dis Int* 2009; **8**: 424.
- Zajko AB, Claus D, Clapuyt P, et al. Obstruction to hepatic venous drainage after liver transplantation: treatment with balloon angioplasty. *Radiology* 1989; **170**: 763.
- Egawa H, Tanaka K, Uemoto S, et al. Relief of hepatic vein stenosis by balloon angioplasty after living-related donor liver transplantation. *Clin Transplant* 1993; **7**: 306.
- Sze DY, Semba CP, Razavi MK, Kee ST, Dake MD. Endovascular treatment of hepatic venous outflow obstruction after piggyback technique liver transplantation. *Transplantation* 1999; **68**: 446.
- Egawa H, Inomata Y, Uemoto S, et al. Hepatic vein reconstruction in 152 living-related donor liver transplantation patients. *Surgery* 1997; **121**: 250.
- Dindo D, Demartines N, Clavien PA. Classification of surgical complications: a new proposal with evaluation in a cohort of 6336 patients and results of a survey. *Ann Surg* 2004; **240**: 205.
- Belghiti J, Panis Y, Sauvanet A, Gayet B, Fekete F. A new technique of side to side caval anastomosis during orthotopic hepatic transplantation without inferior vena caval occlusion. *Surg Gynecol Obstet* 1992; **175**: 270.
- Ng SS, Yu SC, Lee JF, Lai PB, Lau WY. Hepatic venous outflow obstruction after piggyback liver transplantation by an unusual mechanism: report of a case. *World J Gastroenterol* 2006; **12**: 5416.
- Settmacher U, Nussler NC, Glanemann M, et al. Venous complications after orthotopic liver transplantation. *Clin Transplant* 2000; **14**: 235.
- Parrilla P, Sanchez-Bueno F, Figueras J, et al. Analysis of the complications of the piggy-back technique in 1,112 liver transplants. *Transplantation* 1999; **67**: 1214.
- Vilca Melendez H, Rela M, Heaton ND. Replacement of the retrohepatic vena cava in segmental liver transplantation. *Transpl Int* 1997; **10**: 475.
- Someda H, Moriyasu F, Fujimoto M, et al. Vascular complications in living related liver transplantation detected with intraoperative and postoperative Doppler US. *J Hepatol* 1995; **22**: 623.
- Quintela J, Fernandez C, Aguirrezabalaga J, et al. Early venous outflow obstruction after liver transplantation and treatment with cavo-cavostomy. *Transplant Proc* 2009; **41**: 2450.
- Khan S, Silva MA, Tan YM, et al. Conventional versus piggyback technique of caval implantation; without extra-corporeal veno-venous bypass. A comparative study. *Transpl Int* 2006; **19**: 795.
- Kubo T, Shibata T, Itoh K, et al. Outcome of percutaneous transhepatic venoplasty for hepatic venous outflow obstruction after living donor liver transplantation. *Radiology* 2006; **239**: 285.
- Hadengue A, Poliquin M, Vilgrain V, et al. The changing scene of hepatic vein thrombosis: recognition of asymptomatic cases. *Gastroenterology* 1994; **106**: 1042.

35. Ko GY, Sung KB, Yoon HK, *et al.* Early posttransplant hepatic venous outflow obstruction: long-term efficacy of primary stent placement. *Liver Transpl* 2008; **14**: 1505.
36. Lee S, Park K, Hwang S, *et al.* Anterior segment congestion of a right liver lobe graft in living-donor liver transplantation and strategy to prevent congestion. *J Hepatobiliary Pancreat Surg* 2003; **10**: 16.
37. Fan ST, Lo CM, Liu CL, Yong BH, Wong J. Determinants of hospital mortality of adult recipients of right lobe live donor liver transplantation. *Ann Surg* 2003; **238**: 864; discussion 9–70.
38. Huang TL, Chen TY, Chen CL, *et al.* Hepatic outflow insults in living-related liver transplantation: by Doppler sonography. *Transplant Proc* 2001; **33**: 3464.
39. Raby N, Karani J, Thomas S, O'Grady J, Williams R. Stenoses of vascular anastomoses after hepatic transplantation: treatment with balloon angioplasty. *AJR Am J Roentgenol* 1991; **157**: 167.
40. Borsa JJ, Daly CP, Fontaine AB, *et al.* Treatment of inferior vena cava anastomotic stenoses with the Wallstent endoprosthesis after orthotopic liver transplantation. *J Vasc Interv Radiol* 1999; **10**: 17.
41. Krishna Kumar G, Sharif K, Mayer D, *et al.* Hepatic venous outflow obstruction in paediatric liver transplantation. *Pediatr Surg Int* 2010; **26**: 423.
42. Rossi AR, Pozniak MA, Zarvan NP. Upper inferior vena caval anastomotic stenosis in liver transplant recipients: Doppler US diagnosis. *Radiology* 1993; **187**: 387.
43. Coulden RA, Lomas DJ, Farman P, Britton PD. Doppler ultrasound of the hepatic veins: normal appearances. *Clin Radiol* 1992; **45**: 223.
44. Chong WK, Beland JC, Weeks SM. Sonographic evaluation of venous obstruction in liver transplants. *AJR Am J Roentgenol* 2007; **188**: W515.
45. Ducerf C, Rode A, Adham M, *et al.* Hepatic outflow study after piggyback liver transplantation. *Surgery* 1996; **120**: 484.
46. Funaki B, Rosenblum JD, Leef JA, *et al.* Percutaneous treatment of portal venous stenosis in children and adolescents with segmental hepatic transplants: long-term results. *Radiology* 2000; **215**: 147.
47. Quintini C, Miller CM, Hashimoto K, *et al.* Side-to-side cavocavostomy with an endovascular stapler: rescue technique for severe hepatic vein and/or inferior vena cava outflow obstruction after liver transplantation using the piggyback technique. *Liver Transpl* 2009; **15**: 49.
48. Cheng YF, Huang TL, Chen CL, *et al.* Intraoperative Doppler ultrasound in liver transplantation. *Clin Transplant* 1998; **12**: 292.
49. Mazariegos GV, Garrido V, Jaskowski-Phillips S, Towbin R, Pigula F, Reyes J. Management of hepatic venous obstruction after split-liver transplantation. *Pediatr Transplant* 2000; **4**: 322.
50. Stafford-Johnson DB, Hamilton BH, Dong Q, *et al.* Vascular complications of liver transplantation: evaluation with gadolinium-enhanced MR angiography. *Radiology* 1998; **207**: 153.
51. Orons PD, Zajko AB, Bron KM, Trecha GT, Selby RR, Fung JJ. Hepatic artery angioplasty after liver transplantation: experience in 21 allografts. *J Vasc Interv Radiol* 1995; **6**: 523.
52. Yamagiwa K, Yokoi H, Isaji S, *et al.* Intrahepatic hepatic vein stenosis after living-related liver transplantation treated by insertion of an expandable metallic stent. *Am J Transplant* 2004; **4**: 1006.
53. Brostoff JM, Bhati CS, Syn WK. Late venous outflow obstruction after liver transplant: the 'piggy-back' syndrome. *Eur J Intern Med* 2008; **19**: 374.
54. Mentha G, Giostra E, Majno PE, *et al.* Liver transplantation for Budd-Chiari syndrome: a European study on 248 patients from 51 centres. *J Hepatol* 2006; **44**: 520.
55. Horton JD, San Miguel FL, Membreno F, *et al.* Budd-Chiari syndrome: illustrated review of current management. *Liver Int* 2008; **28**: 455.