

## Donor-derived malignancy in a pancreas graft

doi:10.1111/j.1432-2277.2009.00989.x

Donor-transmitted tumors may occur in about 0.02% of solid organ recipients [1]. Considering the rarity of these events, the case of a patient who developed malignancy in a pancreatic graft derived from a donor with a malignant glioma as the cause of brain death is reported.

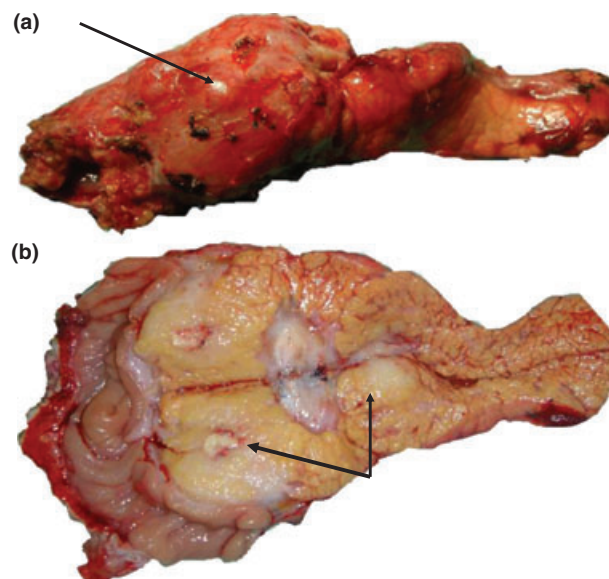
A 11-year-old white female child who had died from a malignant glioma was the organ donor. She had been diagnosed with malignant glioma by the age of 4 when a first craniotomy was performed and the tumor removed. Histological findings revealed a grade III pleomorphic xanthoastrocytoma. She was followed for 6 years asymptotically up to the age of 10. By this time, she presented with seizures and headache episodes and a new surveillance showed recurrent cerebral tumor. Three consecutive craniotomies were performed within a period of 6 months for removal of the recurrent tumor. After the fourth craniotomy, she was evaluated for intracranial hypertension and progression to brain death. No ventriculo-peritoneal shunt, chemo- or radiotherapy was performed during the follow-up. By the time of recovery of organs, no intra-abdominal or intra-thoracic abnormalities were noticed. Heart, liver, one kidney and pancreas were recovered for transplant in different recipients. One kidney was not used because of anatomical problems. Macroscopic appearance of the pancreas was normal.

A pancreas transplant alone (PTA) was performed in a 21-year-old male patient, who had been diabetic for 19 years. The indication of the transplant was based on the presence of two secondary complications of the diabetes, including an advanced retinopathy and moderate nephropathy (proteinuria of 1.14 g/24 h and a creatinine clearance of 66 ml/min). Surgical technique consisted of bladder and systemic venous drainage with a total ischemia time of 6 h and 10 min. A quadruple sequential immunosuppression regimen was employed with thymoglobulin, mycophenolate mofetil, tacrolimus and prednisone. Early postoperative outcome was uneventful and the patient was discharged insulin-free 12 days post-transplant.

No imaging study was performed until the 4th postoperative month according to our routine protocol for uncomplicated pancreas transplant recipients.

By this time, the patient developed abdominal pain and an allograft pancreatic mass was diagnosed in an ultrasonography and confirmed by a CT scan. An ultrasound-guided biopsy was performed and revealed a malignant anaplastic tumor, compatible with glioma. A retrospective comparison between donor- and recipient histological findings was carried out and this study confirmed the same malignant glioma in both patients, classified as a grade III pleomorphic xanthoastrocytoma by immunohistochemical staining. A graft pancreatectomy was performed and the surgical finding was a tumor limited to the head of the pancreas with no suspected infiltrative tissues or lymph nodes surrounding the graft (Fig. 1). Immunosuppression was promptly discontinued and the patient was restored to insulin.

A strict follow-up has been done, with thoracic and abdominal CT scans performed every 6 months. His clinical evolution has been uneventful and the patient is stable and malignancy-free 5 years after graft removal.



**Figure 1** Macroscopic aspect of graft pancreatectomy. (a) External view of the pancreas shows enlargement mostly in the head/body; (b) Exposed neoplasia (arrows) in the head and body of the resected pancreatic graft.

The heart and liver recipients died in the first few days post-transplant; the former as a result of respiratory problems and the latter because of cerebral hemorrhage. The kidney recipient was an 81-year-old female who was informed about the donor diagnosis and decided not to have the kidney graft removed despite the risks. Currently, she presents with a stable kidney graft function and is apparently tumor-free during regular follow-up.

Primary tumors of central nervous system (CNS) only rarely produce extraneural metastases and organs from donors with primary brain malignancy have long been used for transplantation [2].

The risk of donor-transmitted malignancy has led to caution in the use of donors with CNS and other tumors. However, reports of these donors being used without transmission remain controversial [3].

In a recent report from Organ Procurement and Transplantation Network (OPTN), the donor-transmission tumor rate was 0.017% in 110 402 kidney-, 0.009% in 11 536 kidney-pancreas-, 0.026% in 62 429 liver-, 0.01% in 28 815 heart- and 0.062% in 12 998 lung transplant recipients [1].

The great majority of cases presented a time duration from transplantation to tumor transmission within the first 2 years post-transplant [1]. Factors associated with an increased risk of cancer transmission are high-grade malignancy, previous craniotomy, the presence of ventricular systemic shunt, previous radiotherapy and a long time-interval between primary therapy and disease relapse [2].

In this case, several of these risk factors were confirmed such as four previous craniotomies, grade III astrocytoma and an interval of 6 years between the primary diagnosis and the disease relapse. Besides, the tumor did occur in a relatively early post-transplant period (only 4 months) and was developed in the own graft.

If donor-transmitted malignancy occurs, graft removal and prompt cessation of immunosuppression may lead to complete resolution of the disease. Indeed, this was the strategy of treatment in this case and the patient has been apparently tumor-free 5 years post-transplant.

Although the concern about risk of cancer from repeated CT scanning, it was considered that the possibility of a recurrent glioma in this individual case exceeded the previous issue and a strict imaging follow-up was established. Indeed, the risk of malignancy caused by

radiation exposure seems to be small on an individual basis and more importantly in a large population and as a public health issue for some years in the future [4].

The findings of this case report confirmed that although primary tumors of CNS comprise a relatively small proportion of deceased organ donors (<5%), they may transmit malignancy to recipients, particularly if one or more risk factors are involved. Therefore, the risk of tumor transmission needs to be weighed very carefully against the chances of the recipients dying or becoming sicker while being on the waiting list [2].

This case seems to be the first donor-transmitted tumor in a PTA recipient. Although it is a low-risk category of recipient and an alternative donor might have been chosen, it was considered at that moment that a very young donor with apparently healthy organs would outweigh the risks of tumor transmission.

Based on this personal experience and review of literature, we decided from this point onwards not to accept organs from donors with primary tumors of CNS if any risk factor is involved.

Marcelo Perosa, Fabio Crescentini, Irina Antunes,  
Giovanni Marchini, Sergio Rosemberg,  
Alanna Bezerra and Tercio Genzini  
*Department of Transplant, Albert Einstein Hospital,  
Sao Paulo, Brazil*

## References

1. Kauffman HM, McBride MA, Cheriakh WS. Malignancies in solid organ transplantation. In: Grinyó J, ed. *Malignancies in Solid Organ Transplant Recipients. International Transplantation Updates*. Barcelona, Spain: Permaneyer Publications, 2009: 1–14.
2. Drage M, Watson CJ, Bradley JA. Clinical features and management. In: Grinyó J. ed. *Malignancies in Solid Organ Transplant Recipients. International Transplantation Updates*. Barcelona, Spain: Permaneyer Publications, 2009:35–48.
3. Buell JF, Trofe J, Sethuraman G, *et al.* Donors with central nervous system malignancies : are they truly safe? *Transplantation* 2003; **76**: 340.
4. Brenner DJ, Hall EJ. Current concepts: computed tomography – an increasing source of radiation exposure. *N Eng J Med* 2007; **357**: 2277.