

Tetsushi Kitagawa
Yonson Ku
Nobuya Kusunoki
Masahiro Tominaga
Ichiro Maeda
Takumi Fukumoto
Takeshi Iwasaki
Yoshikazu Kuroda
Yoichi Saitoh

Pharmacokinetics of intravenous adriamycin for anhepatic chemotherapy during liver transplantation

T. Kitagawa · Y. Ku (✉) · N. Kusunoki ·
M. Tominaga · I. Maeda · T. Fukumoto ·
T. Iwasaki · Y. Kuroda · Y. Saitoh
First Department of Surgery, Kobe
University School of Medicine, 7-5-2
Kusunoki-cho, Chuo-ku, Kobe 650, Japan

Abstract Frequent recurrence of hepatocellular carcinoma after liver transplantation indicates the necessity to eliminate patients with advanced disease and combine transplantation with some form of perioperative adjuvant chemotherapy. This study was undertaken to elucidate adriamycin pharmacokinetics for anhepatic chemotherapy during liver transplantation. Beagles of both sexes were allocated into two groups, controls ($n = 4$) and anhepatic animals with total hepatectomy under venovenous bypass ($n = 5$). In both groups, adriamycin was administered in 1 min at a dose of 1 mg/kg through the left antecubital vein and peripheral blood was obtained at intervals for up to 2 h to determine the plasma adriamycin levels. The animals were then sacrificed to determine tissue adriamycin levels in the liver, kidney, heart, lung, and skeletal muscle. Plasma adriamycin levels in anhepatic animals were significantly higher than those in controls at all

measured time points after 10 min, resulting in a 50 % reduction of the mean total body clearance of adriamycin compared with controls ($P < 0.01$). However, there was no statistically significant difference in adriamycin levels between the two groups for all measured tissues except for the liver. Despite the complete lack of hepatic function, anhepatic animals showed only a 50 % reduction in total body clearance of adriamycin compared with normal controls, probably due to compensatory excretion from other organs such as the kidney. These results suggest that systemic chemotherapy with the standard dose of adriamycin may be tolerable during the anhepatic period of liver transplantation with enhanced tumoricidal effects on micrometastases.

Key words Anhepatic chemotherapy · Liver transplantation · Adriamycin pharmacokinetics · Malignant liver tumor

Introduction

Surgical removal is the only chance for cure in patients with hepatocellular carcinoma. Unfortunately, candidates for hepatectomy are limited to only 10–30 % of the patients at the time of diagnosis, either by virtue of the extent of the tumor or by the lack of hepatic functional reserve [1, 2]. Furthermore, even when resectable, recurrence rates after hepatectomy are unacceptably high [3, 4].

Orthotopic liver transplantation had been advocated as the ultimate treatment for the potential cure of the disease. Despite early enthusiasm, however, it became evident that recurrence either in the transplanted liver or in extrahepatic sites developed in the majority of patients [5, 6]. In response to dismal outcomes, several transplant centers have recently conducted pre-, intra-, and postoperative adjuvant chemotherapies to improve prognosis after liver transplantation [7–9]. As a logical extension to intraoperative systemic chemotherapy

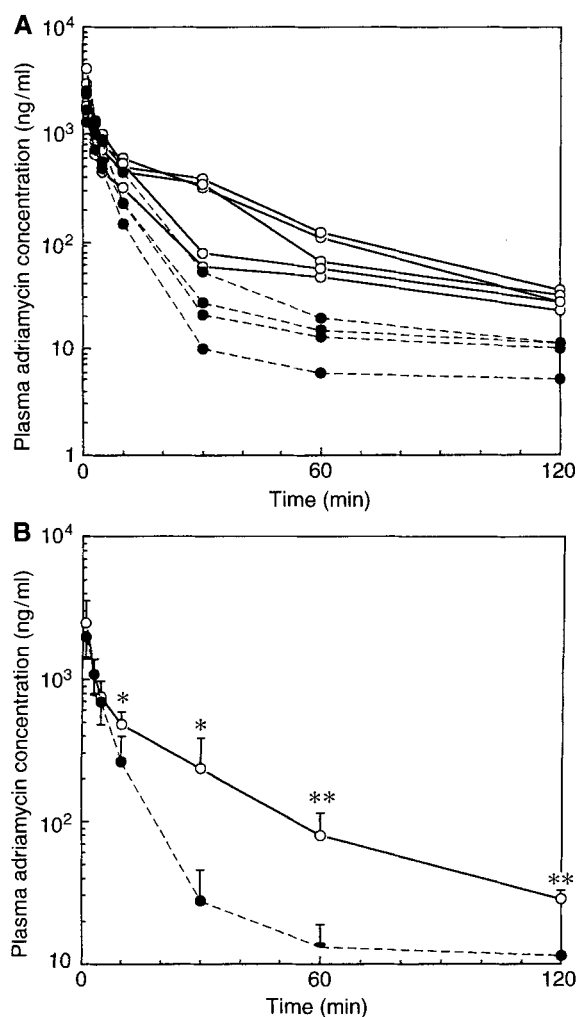


Fig. 1 A, B A semilogarithmic plot of the time course of plasma adriamycin concentrations. **A** Individual dog. **B** Mean \pm SD in each group. (\bullet Control dogs, \circ anhepatic dogs; * $P < 0.05$, ** $P < 0.01$ vs controls)

with orthotopic liver transplantation, anhepatic chemotherapy seems to emerge to give a tumoricidal impact on micrometastases that have spread beyond the liver. However, to our knowledge, anhepatic chemotherapy has not been described previously and its safety is still uncertain. We herein investigated the pharmacokinetics of adriamycin when administered during the anhepatic period of liver transplantation.

Materials and methods

Beagles of both sexes weighing 7.0–8.1 kg were used for this study. The animals were fasted overnight and anesthetized using pentobarbital, 25 mg/kg i.v., and pancuronium bromide, 0.1 mg/kg i.v., as an induction dose. After endotracheal intubation, animals were mechanically ventilated during the experiment. An arterial line

was placed into the left carotid artery for blood pressure and heart rate monitoring. Lactate-Ringer's solution (10 ml/kg body weight per h) was administered intravenously during the procedure. A midline laparotomy was simply performed in group 1, controls ($n = 4$). On the other hand, in group 2 anhepatic animals ($n = 5$), the liver was mobilized and isolated by dividing all of its peritoneal attachments. Subsequently a pump-driven venovenous bypass from the inferior vena cava and the portal vein to the left jugular vein was constructed, as described previously [10]. Under venovenous bypass, the supra- and infrahepatic inferior vena cava and the portal vein were clamped and the liver was removed.

In both groups, a 1-min bolus injection of adriamycin, 1 mg/kg was performed through the left antecubital vein. Blood samples were obtained from the carotid artery (for monitoring systemic drug levels) just before and 1, 3, 5, 10, 30, 60, 90, and 120 min after drug infusion. The animals were then sacrificed to determine tissue adriamycin levels in the liver (only for group 1), kidney, heart, lung, and skeletal muscle. Plasma adriamycin levels were determined by high-performance liquid chromatography (HPLC) using the method described previously [11]. In brief, aliquots of plasma were placed on mini-columns (Nucleosil 5C 18; Chemo Company, Japan). After washing, the drug was eluted and the eluent was dried under vacuo. Samples were then redissolved in mobile phase before injection into the HPLC. A routine internal standard of adriamycin was used to account for assay variability. Tissue adriamycin levels were analyzed by homogenizing the tissue and then performing a chloroform-methanol centrifugation extraction of adriamycin from the homogenate. The phase containing the extracted adriamycin was washed and eluted, and the eluent was dried under nitrogen. Samples were then redissolved in HPLC mobile phase and adriamycin levels were measured by routine HPLC. The area under the time concentration curve was calculated by the trapezium method.

Student's two-tailed t -test was used for statistical analysis of the results. Differences were considered significant at the 5% level.

Results

No significant differences were found in mean arterial pressure and heart rate between the two groups throughout the experiment. The semilogarithmic plots of the plasma concentration-time data for adriamycin in both groups are illustrated in Fig. 1. The plasma levels reached peak values of 2.0 ± 0.6 (means \pm SD) and 2.5 ± 1.1 $\mu\text{g/ml}$, respectively, in groups 1 and 2, 1 min after drug infusion. Thereafter, the levels in groups 1 and 2 promptly decreased to 0.7 ± 0.2 and 0.8 ± 0.2 at 5 min. During the initial 5 min, no significant difference was noted in plasma adriamycin levels between the two groups. Subsequently, group 2 animals had significantly higher plasma adriamycin levels at all measured time points from 10 to 120 min compared to group 1. As shown in Fig. 1 A, two distinctive phases were identified in each animal. During the distribution phase, the mean plasma half-lives were similar in both groups; the mean values were 3.2 ± 0.8 min and 2.4 ± 1.6 min, respectively, in groups 1 and 2. On the other hand, the mean elimination half-life of 62.7 ± 17.3 min in group 1 tended to be longer than that of 47.4 ± 19.8 min in group 2.

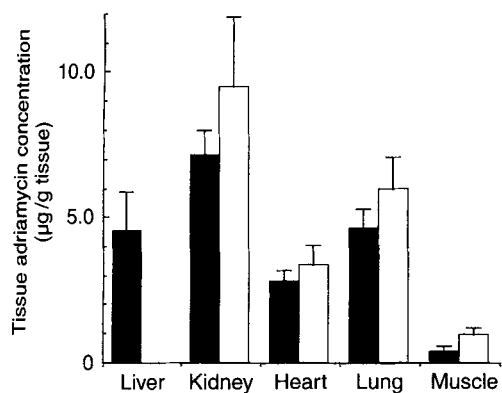


Fig. 2 Tissue adriamycin concentrations. (■ Control dogs, □ anhepatic dogs) Values are expressed as mean \pm SD

The mean areas under the concentration-time curves were 12.4 ± 4.1 and 24.9 ± 8.0 $\mu\text{g}/\text{ml}$ per min, respectively, in groups 1 and 2, showing a two-fold increase in group 2 compared with group 1 ($P < 0.01$). Conversely, the mean total body clearance of adriamycin showed a 50% reduction in group 2 compared with group 1.

Figure 2 shows tissue adriamycin levels in five organs including the liver (only for group 1), kidney, heart, lung, and skeletal muscle. Tissue levels in the heart were 2.8 ± 0.4 and 3.4 ± 0.7 $\mu\text{g}/\text{g}$ tissue, respectively, in groups 1 and 2, showing no statistically significant difference. Similarly, all other tissues, except for the liver, showed a higher drug level in group 2 than in group 1, although statistically this was not significant.

Discussion

Adriamycin has been widely used as a potent cytotoxic agent for the treatment of malignant liver tumors. Major dose-limiting toxicities of adriamycin include myelosuppression and delayed cardiac dysfunction, which become frequent when systemic plasma levels exceed 1.0 $\mu\text{g}/\text{ml}$ [12] and a cumulative dose reaches around 500 mg/m^2 [13]. Previous studies demonstrated that the liver is the major organ rich in key enzymes responsible for adriamycin metabolism and that the drug is mainly excreted from the hepato-biliary system [14]. Thus, any

given dose may be more effective, but also more toxic, under the anhepatic condition. With these considerations in mind, we investigated adriamycin pharmacokinetics under the complete hepatectomized condition for safe and effective performance of anhepatic chemotherapy during liver transplantation.

Anhepatic chemotherapy has a theoretical advantage in that it could minimize drug exposure to the liver allograft. In the clinical setting, the liver allograft is subjected to a variety of insults such as ischemia during organ harvest, cold preservation, and subsequent reperfusion. Thus, it is unadvisable to administer a potentially hepatotoxic drug shortly after reperfusion. According to the plasma profile in this study, adriamycin levels reached a near steady-state by 60 min, even in anhepatic animals, and the values at 60 min were less than 3% of the peak levels. Provided that the anhepatic period in orthotopic liver transplantation averages 60 min, it is reasonable to speculate that a bolus injection of adriamycin at the beginning of the anhepatic period would exhibit only a marginal toxic effect on the liver allograft.

As shown in Fig. 1, two distinctive phases consisting of the distribution and the elimination phases were identified in the concentration-time curve of anhepatic animals as well as normal controls. During the distribution phase, both groups showed similar plasma levels of adriamycin, reflecting a rapid tissue uptake of the drug in various organs during the first pass. As a result, there was no significant difference in the plasma half-life during this phase between the two groups. In contrast, during the elimination phase, plasma half-life tended to be shortened in anhepatic animals. It is most likely that higher plasma levels of adriamycin may enhance compensatory drug excretion through extrahepatic organs such as the kidney, although a definitive conclusion should wait further study investigating urinary drug excretion under anhepatic conditions.

In terms of total body clearance, anhepatic dogs exhibited only a 50% reduction compared to that of normal controls. Furthermore, tissue adriamycin concentrations in five measured organs did not differ significantly between the two groups. These results indicate that the standard dose of adriamycin may be theoretically tolerable and enhance tumoricidal effects on extrahepatic micrometastases during the anhepatic period.

References

- Okuda K, Otsuki T, Obata H (1985) Natural history of hepatocellular carcinoma and prognosis in relation to treatment. Study of 850 patients. *Cancer* 56: 918–928
- The Liver Cancer Study Group of Japan (1987) Primary liver cancer in Japan. Sixth report. *Cancer* 60: 1400–1411
- Belghiti J, Panis Y, Farges O, Benhamou JF, Fekete F (1991) Intrahepatic recurrence after resection of hepatocellular carcinoma complicating cirrhosis. *Ann Surg* 214: 114–117
- Sasaki Y, Imaoka S, Fujita M (1987) Regional therapy in the management of intrahepatic recurrence after surgery for hepatoma. *Ann Surg* 206: 40–47
- Iwatsuki S, Starzl TE, Seahan DG (1991) Hepatic resection versus transplantation for hepatocellular carcinoma. *Ann Surg* 214: 221–229

6. Olthoff KM, Millis JM, Rosove MH, Goldstein LJ, Ramming KP, Busutill RW (1990) Is liver transplantation justified for the treatment of hepatic malignancies? *Arch Surg* 125: 1261–1268
7. Stone MJ, Klintmalm GB, Polter, Husberg BOS, Mennel RG, Ramsay MAE, Flemens EE, Goldstein RM (1993) Neoadjuvant chemotherapy and liver transplantation for hepatocellular carcinoma: results in 20 patients. *Gastroenterology* 104: 196–202
8. Carr BI, Starzl TE, Iwatsuki S, Van Thiel D (1991) Aggressive treatment for advanced hepatocellular carcinoma (HCC): high recurrence rates and prolonged survival. *Hepatology* 14: 103A
9. Cherqui D, Piedbois P, Pierga J, Duvoux C, Vavasseur D (1994) Multimodal adjuvant treatment and liver transplantation for advanced hepatocellular carcinoma. *Cancer* 73: 2721–2726
10. Kam I, Lynch S, Todo S, Dewolf A, McSteen F, Jakab F, Ericzon BG (1986) Low flow venovenous bypass in small dogs and pediatric patients undergoing replacement of the liver. *Surg Gynecol Obstet* 163: 33–36
11. Robert J (1980) Extraction of anthracycline from biologic fluids for HPLC evaluation. *J Liquid Chromatogr* 3: 1561–1572
12. Legha SS, Benjamin RS, Mackay B (1982) Reduction of doxorubicin cardiotoxicity by prolonged continuous intravenous infusion. *Ann Intern Med* 96: 133–139
13. Benjamin RS, Wiernik PH, Bachur NR (1974) Adriamycin chemotherapy—efficacy, safety and pharmacologic basis of an intermittent single high-dose schedule. *Cancer* 33: 19–26
14. Loveless H, Arena E, Felsted RL (1978) Comparative mammalian metabolism of adriamycin and daunorubicin. *Cancer Res* 38: 593–598