

## ORIGINAL ARTICLE

## The linear cutting stapler for enteric anastomosis: a new technique in pancreas transplantation

Vincent W. T. Lam, Kit Wong, Wayne Hawthorne, Brendan Ryan, Howard Lau, Paul Robertson, Richard D. M. Allen and Henry Pleass

National Pancreas Transplant Unit, Westmead Hospital and Discipline of Surgery, University of Sydney, NSW, Australia

### Keywords

anastomosis, pancreas transplantation, stapler.

### Correspondence

Henry Pleass, Department of Surgery, Westmead Hospital, Westmead, NSW 2145, Australia. Tel.: +61 2 9845 6821; fax: +61 2 9893 7440; e-mail: henry\_pleass@wsahs.nsw.gov.au

Received: 6 April 2006

Revision requested: 24 April 2006

Accepted: 14 June 2006

doi:10.1111/j.1432-2277.2006.00368.x

### Summary

The drainage of pancreatic exocrine secretions following pancreas transplantation is an evolving area of surgical practice. We describe a new technique applying a 55 mm Linear Cutting Stapler (LCS) to create the duodenoenterostomy for enteric drainage of the pancreas transplant. Twenty simultaneous pancreas and kidney transplantations performed between April 2005 and March 2006 were reviewed. Using a prospective database and chart review, complications and outcome related to the new technique of exocrine drainage were described. During this 12 month period, 19 of 20 consecutive simultaneous pancreas and kidney transplantations have been performed using the linear cutting stapler technique. No complications relating to the enteric anastomosis have been demonstrated. In our initial experience, use of the LCS is both safe and easy to perform.

### Introduction

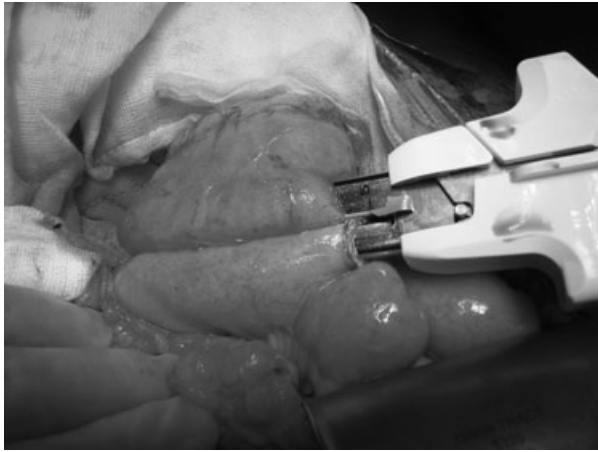
Whole vascularized pancreas transplantation is the only treatment option capable of providing proven long-term restoration of glucose metabolism, in patients with type 1 diabetes mellitus. The surgical technique has been crucial to the success and evolution of this procedure. A survey of pancreas transplant units prior to the 6th Congress of the International Pancreas and Islet Association in Milan 1997, described 39 variations of the pancreas transplant procedure [1]. Enteric drainage of pancreas exocrine secretions from the donor duodenum to recipient small bowel is the commonest technique used worldwide although bladder drainage remains in regular clinical practice [2]. The enteric drainage technique is the most physiological technique for drainage of exocrine pancreatic secretions and could prevent the metabolic and urological complications associated with bladder drainage.

Intestinal anastomoses have been successfully performed for more than 150 years using a variety of techniques, materials and devices. Since the introduction of

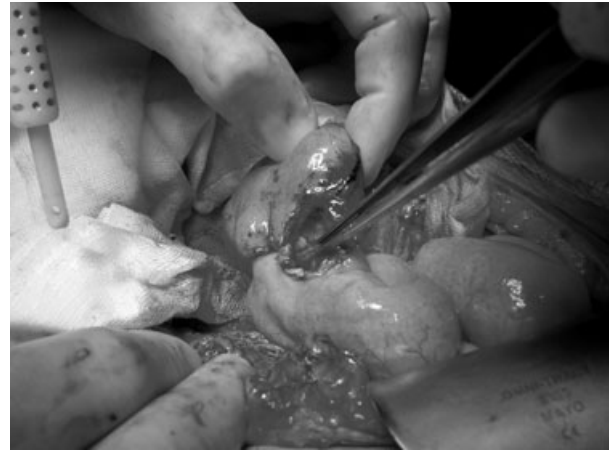modern stapling devices and techniques during the 1950s, staplers have been shown to reduce time, peritoneal contamination and tissue trauma, while creating an intestinal anastomosis [3]. In this article, we describe a technique applying a 55 mm linear cutting stapler (LCS) (TLC55, Ethicon Endo-Surgery, Inc., Sydney, Australia) to create the duodenoenterostomy for enteric drainage of the pancreas transplant.

### Surgical technique

The pancreas is procured using an *en bloc* technique after aortic flush with preservation solution as previously described [4]. Back-table preparation of the pancreas graft is carried out before implantation. Graft duodenum is fashioned to appropriate length with two fires of the LCS. The staple line on the proximal duodenum is inverted with continuous 3.0 Polydioxanone (PDS) suture (Ethicon Inc). A portal vein extension graft and iliac artery extension Y grafts are routinely used in back-table preparation. Minimal portal vein extension is used as necessary



**Figure 1** Linear cutting stapler arms inserted into donor duodenum and recipient jejunum.

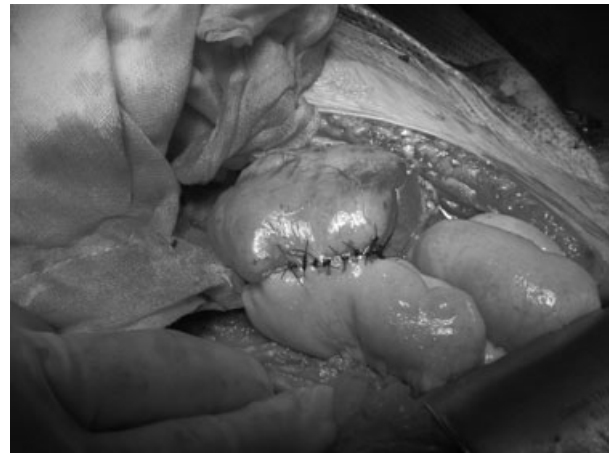


**Figure 2** Check of bleeding of stapled lines before closure of enterotomy.

to construct a tension free anastomosis. This minimizes the risk of portal vein kinking and thrombosis [5].

We typically implant the pancreas in an intraperitoneal position onto the right iliac vessels. The head of pancreas and duodenum are oriented inferiorly to provide an option for creation of a duodenovesical anastomosis if the blood supply to the donor duodenum is suboptimal after reperfusion.

After the pancreas has been reperfused and haemostasis obtained, the recipient's proximal jejunum is identified and a site selected for anastomosis to the graft duodenum chosen whereby the anastomosis will be without tension. Noncrushing bowel clamps are applied to jejunum either side of the anastomosis site. Small longitudinal enterotomies of less than a centimetre are made along the anti-mesenteric borders of the distal donor duodenum and recipient jejunum. The donor duodenal segment is then rinsed out with 0.5% aqueous chlorhexidine. The LCS is then inserted into each limb of the bowel (Fig. 1). The stapler arms are brought tightly together and the bowel is checked on each side to ensure that no mesentery is included within the staple line. The LCS is then fired and the arms of the LCS are opened and removed. Bleeding along the staple line is checked and controlled if present by 3.0 PDS interrupted sutures (Fig. 2). The confluent stapled entry site is closed with 3.0 PDS interrupted sutures. Thus, a side-to-side duodenoenteric anastomosis is created. The remaining duodenal staple line created on the back-table is then oversewn with a continuous 3.0 PDS suture (Fig. 3). Care is taken to allow sufficient duodenum for the creation of a subsequent duodenovesical anastomosis if required. In addition, a single interrupted 3.0 PDS suture is placed at the crotch of the anastomosis.



**Figure 3** Final side-to-side duodeno-jejunal anastomosis.

## Results

Between April 2005 and March 2006, 19 of 20 consecutive simultaneous pancreas and kidney transplantations have been performed using the LCS technique. One patient was readmitted 6 weeks after transplantation with melana, presumably bleeding from the stapler line, the only complication that could be attributed to the enteric anastomosis. This was managed conservatively with no intervention required. Another patient has developed a pancreatic fistula 4 weeks after transplantation secondary to an episode of early graft pancreatitis. Re-laparotomy revealed pancreatic leak from the tail, which was since settled and the patient is now well with good pancreatic graft function. A further patient required re-laparotomy 16 days after transplantation to remove a nonviable pancreas transplant secondary to venous thrombosis.

## Discussion

Stapling devices have gained widespread popularity in construction of intestinal anastomoses because of their safety and reliability [3]. In theory, the benefits of a stapled intestinal anastomosis include better blood supply, reduced tissue manipulation, minimum oedema, uniformity of sutures, adequate lumen at sites of anastomosis and ease and rapidity of anastomosis [6]. A meta-analysis of 13 randomized controlled trials comparing handsewn with stapled colonic anastomosis showed similar clinical and radiologic leak rates [7]. Despite over three decades of refinements of surgical technique, anastomotic leaks postpancreas transplantation remains a clinical significant entity. For enteric-drained case series, leak rates of 4–9% have been reported [8–10]. Risk factors for early leaks include anastomotic tension on the enteroenterostomy, severe reperfusion duodenitis and use of steroids and other immunosuppressants. Late leaks are frequently because of duodenal perforation secondary to infectious ulcers from cytomegalovirus (CMV).

In 1989, Pescovitz *et al.* first described the use of circular stapler in construction of duodenocystostomy for bladder drainage of the pancreas transplant [11]. Recently, the use of a circular stapler to create a side-to-side duodenoenterostomy for enteric drainage of the pancreas transplant has also been documented with a consistently low complication rate [12,13]. In 1998, a survey of pancreas transplant units around the world reported that duodenoenterostomy was performed using a circular stapler by five different institutions. No use of LCS was documented.

In this series, using an anastomosis constructed with LCS, there have been no anastomotic leaks, results which compare favourably with other published series [9,12,14–16]. The confluent stapled entry site used to insert the arms of the LCS is closed with a single layer interrupted PDS suture rather than another fire of linear stapler. This ensures no narrowing of the donor duodenum or recipient's jejunum. This in turn minimizes tension applied to the anastomosis from distension of the narrowed small intestine. PDS was chosen as the suture material of choice in our series as it has been shown to have high resistance to the digestive effect of pancreatic juice and association with less inflammatory reaction [17]. A series of 70 patients underwent pancreas transplantation using hand sutured PDS anastomosis demonstrated no evidence of anastomotic leaks [16]. Compared with a two layered hand sutured anastomosis, anastomosis constructed with LCS is technically easy to construct, creating a tension free anastomosis with minimal trauma and no narrowing of the recipient's jejunum. The close proximity of the confluent stapled entry site and stapled lines made bleed-

ing control easy to perform when compared with anastomosis constructed with circular stapler.

As a LCS is routinely used during the back-table preparation of the donor duodenum, the cost implication of this technique is very acceptable and avoids the need for an additional stapler if a circular stapler is employed.

## Conclusion

In summary, use of a LCS for transplantation of pancreas requiring enteric drainage has not previously been reported. In our initial experience, it is both safe and easy to perform and does not exclude the option of conversion to bladder drainage if required at subsequent laparotomy. To date no patient has developed an enteric leak from the stapled anastomosis. It will remain the technique of choice within our unit, with continued prospective audit.

## References

1. Di Carlo V, Castoldi R, Cristallo M, *et al.* Techniques of pancreas transplantation through the world: an IPITA Center survey. *Transplant Proc* 1998; **30**: 231.
2. International Pancreas Transplant Registry. 2003 *Annual Reports*. Available at: [http://www.iptr.umn.edu/iptr/annual\\_reports.html](http://www.iptr.umn.edu/iptr/annual_reports.html) [Accessed February 28, 2006].
3. Moran BJ. Stapling instruments for intestinal anastomosis in colorectal surgery [see comment]. *Br J Surg* 1996; **83**: 902.
4. Chui AK, Thompson JF, Lam D, *et al.* Cadaveric liver procurement using aortic perfusion only. *Aust N Z J Surg* 1998; **68**: 275.
5. Gruessner RWG. Surgical aspects of pancreas transplantation: donor procedures. In: Gruessner RWG, Sutherland DER, eds. *Transplantation of the Pancreas*. New York: Springer-Verlag, 2004: 126–142.
6. Didolkar MS, Reed WP, Elias EG, Schnaper LA, Brown SD, Chaudhary SM. A Prospective randomized study of sutured versus stapled bowel anastomoses in patients with cancer. *Cancer* 1986; **57**: 456.
7. McRae HM, McLead RS. Handsewn vs stapled anastomoses in colon and rectal surgery: a meta-analysis. *Dis Colon Rectum* 1998; **41**: 180.
8. Pirsch JD, Odorico JS, D'Alessandro AM, Knechtle J, Becker BN, Sollinger HW. Posttransplant infection in enteric versus bladder-drained simultaneous pancreas-kidney transplant recipients. *Transplantation* 1998; **66**: 1746.
9. Pearson TC, Santamaria PJ, Routenberg KL, *et al.* Drainage of the exocrine pancreas in clinical transplantation: comparison of bladder versus enteric drainage in a consecutive series. *Clin Transplant* 1997; **11**: 201.
10. Kuo PC, Johnson LB, Schweitzer EJ, Bartlett ST. Simultaneous pancreas/kidney transplantation – a comparison of

- enteric and bladder drainage of exocrine pancreatic secretions. *Transplantation* 1997; **63**: 238.
11. Pescovitz MD, Dunn DL, Sutherland DER. Use of the circular stapler in construction of the duodenoneocystostomy for drainage into the bladder in transplants involving the whole pancreas. *Surg Obstet Gynecol* 1989; **169**: 169.
  12. Fridell JA, Milgrom ML, Henson S, Pescovitz MD. Use of the end-to-end anastomotic circular stapler for creation of the duodenoenterostomy for enteric drainage of the pancreas allograft [corrected]. [see comment] [erratum appears in *J Am Coll Surg*. 2004 May;198(5):858]. *J Am Coll Surg* 2004; **198**: 495.
  13. Steurer W, Tabbi MG, Bonatti H, et al. Stapler duodenojejunostomy reduces intraabdominal infection after combined pancreas kidney transplantation as compared with hand-sawn anastomosis. *Transplant Proc* 2002; **34**: 3357.
  14. Sollinger HW, Odorico JS, Knechtle SJ, D'Alessandro AM, Kalayoglu M, Pirsch JD. Experience with 500 simultaneous pancreas-kidney transplants. *Ann Surg* 1998; **228**: 284.
  15. Bloom RD, Olivares M, Rehman L, Raja RM, Yang S, Badosa F. Long-term pancreas allograft outcome in simultaneous pancreas-kidney transplantation: a comparison of enteric and bladder drainage. *Transplantation* 1997; **64**: 1689.
  16. Busing M, Martin D, Schulz T, et al. Pancreas-kidney transplantation with urinary bladder and enteric exocrine diversion: seventy cases without anastomotic complications. *Transplant Proc* 1998; **30**: 434.
  17. Muftuoglu MAT, Ozkan E, Saglam A. Effect of human pancreatic juice and bile on the tensile strength of suture materials. *Am J Surg* 2004; **188**: 200.