

David Talbot
Shlokarth Balupuri
Clemens Gerstenkorn
David Rix
Kamal Abusin
Derek Manas

“En bloc” paediatric renal donors into adult recipients – the Newcastle technique

Received: 23 October 1998
Received after revision: 7 December 1998
Accepted: 21 December 1998

D. Talbot (✉) · S. Balupuri ·
C. Gerstenkorn · D. Rix · K. Abusin ·
D. Manas
Liver and Renal Transplant Unit,
Freeman Hospital, High Heaton,
Newcastle upon Tyne NE7 7DN, UK
Fax: + 44191 223 1191
e-mail: d.talbot@ncl.ac.uk

Abstract Whilst debate still continues about the best use of kidneys from small donors, the techniques used have been varied because of the high vascular thromboses rates and ureteric leak rates. The method described here employs a vessel transposition as described by two German series, but it is combined with an extraperitoneal approach. It is now the method of choice in our unit for such en bloc transplants.

Key words Renal transplantation · En bloc · Paediatric donor

Introduction

Because of the continuing donor shortage, marginal donors, i. e. donors from both ends of the age spectrum, are increasingly being used for transplantation. Because of concern about functional nephron mass as well as the potentially damaging effect of hyperfiltration [20], kidneys from either very young or very old donors are often implanted as double grafts [13]. In the case of the very young donor, technical difficulties with small vessels and ureters are another reason for double renal transplantation [6, 25, 27]. Elevated recipient blood pressure is yet another concern given the high levels of renin from paediatric kidneys [4].

The methods thus far developed have been influenced by the fact that livers from such small donors are in short supply and, therefore, there was never an opportunity for the suprarenal aorta or inferior vena cava to be kept with the renal bloc. Consequently, the standard method has been to oversew the top aorta and inferior vena cava and to anastomose the distal or-

ifices to the recipient iliac vessels [2, 4, 15, 21, 24, 31]. This is especially useful when multiple renal vessels are present as they are effectively preserved. However, one of the main problems of this technique is torsion of the whole block or individual kidneys within the block, which increases the chances of vascular thrombosis [2, 24]. In addition, the block, when completed, generally lies high in the pelvis so that the ureters, which are normally short, have to be brought to the bladder under some degree of tension. Ureteric leaks from the anastomoses and late strictures of the furthest kidney are therefore, greater than with adult kidneys [24, 25, 27].

Different modifications have been suggested to overcome these problems. Firstly, replacement of the external iliac vessels of the recipient by the donor aorta and inferior vena cava has been successfully used [1, 16]. The disadvantage of this technique is the subsequent removal of the graft, particularly if the anastomosis becomes infected. In this case preservation of the arterial blood supply to the leg has to be by a non-anatomical

graft. A patch onlay technique has also been used where the aorta is laid open and the patch, including both renal arteries, is anastomosed to the recipient iliac artery [12]. This is obviously a difficult procedure to perform as it entails working behind both renal arteries making complications more likely. A third technique was described initially by Martins et al. [14], who oversewed the lower aorta and cava and implanted the upper orifices end-to-side to the aorta and inferior vena cava by a transperitoneal approach. The ureters were anastomosed to an ileal conduit. This technique was modified by the Hannover group, who transposed the lower cava and aorta, moving them from the bottom to the top and oversewing the new inferior stumps. The new upper aorta and cava were then anastomosed to the bifurcation of the recipient aorta and cava. This composite graft was then allowed to "drape" down the back of the recipients pelvis and, consequently, the short ureters were not a problem. Occasionally, a patch of bladder (with both ureters) could be used, allowing only a single anastomosis [8, 9]. The problem with such an approach is that it requires a transperitoneal approach for the recipient, with the attendant morbidity. In addition, renal transplant biopsies become a major undertaking with the risk of bowel perforation.

The Newcastle modification of the Hannover method allows for short ureters, avoids the transperitoneal complications and preserves the potential for biopsy.

Method

Thus far, in all but one case, the paediatric kidneys we have transplanted using this modified technique were retrieved from other centres and imported as a block. Communication between donor and recipient teams always occur prior to retrieval. This was in order to stress the importance of having as much aorta and cava below the renal vessels as possible and ureters that were as long as possible, as well as to prevent the harvesting team from splitting the block. The kidneys are flushed with University of Wisconsin solution only. Small adult recipients were chosen and, whilst awaiting the crossmatch result, the block was prepared.

The perinephric fat was removed from both kidneys and then the aorta and cava were carefully skeletonised. The renal vessels were all mobilised to confirm solitary supply to both kidneys. The aorta and cava were then divided just below the renal vessels and the resulting conduits re-anastomosed with interrupted 6-0 prolene above the renal vessels. The new "lower" aorta and cava were then oversewn in two layers with 6-0 prolene (Fig. 2). At this point, accidental torsion of each kidney, as well as of the aorta and cava, becomes increasingly easy to produce. After a further flush with Newcastle UW solution [10] to confirm no leakage, the block was sewn into a swab "sandwich" (Fig. 3).

The recipient was then opened by a standard low Rutherford Morrison incision and the external iliac vessels were displayed. The venous and arterial anastomoses were then constructed with a spatulated donor aorta and IVC using a running 5-0 prolene suture. After clamp release the swab "sandwich" was opened, haemostasis obtained and the ureters were anastomosed to the bladder by two cystostomies using two ureteric stents. At the end of

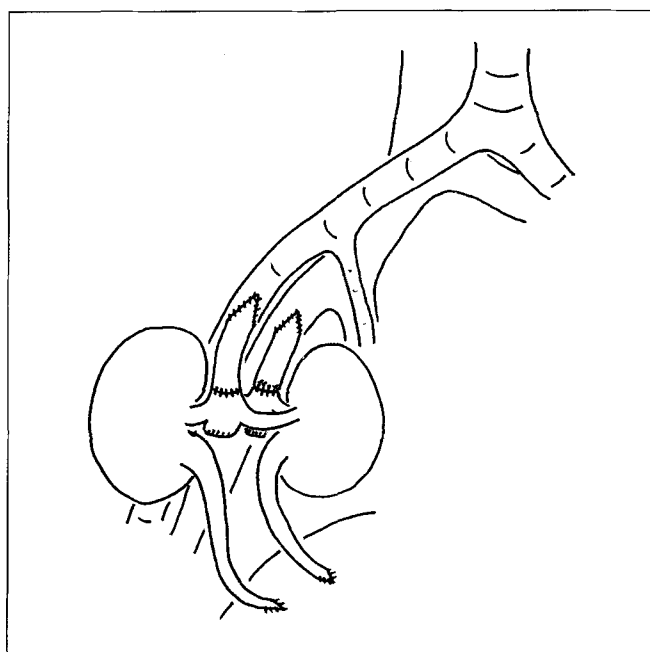


Fig. 1 Diagrammatic representation of the Newcastle technique for paediatric donor renal "en bloc" transplantation

the procedure, the aorta and inferior vena cava lay parallel and above the iliacs with the two kidneys straddling, one on each side. Biopsies are performed when indicated, but "blind" treatment of early rejection is preferred initially to minimise the risk of traumatic arterio-venous fistula as a consequence of biopsy. Initially, acute rejection appeared to be a problem with standard cyclosporin immunosuppression. This was later changed to a tacrolimus regimen with azathioprine and prednisolone, which is now our usual policy. The most appropriate early tacrolimus levels were found to be 10–15 ng/ml. Recipients were initially managed with intravenous heparin, which produced an activated partial thromboplastin time (PTTK) that was twice the normal level, and aspirin was commenced. The latter was continued after discharge.

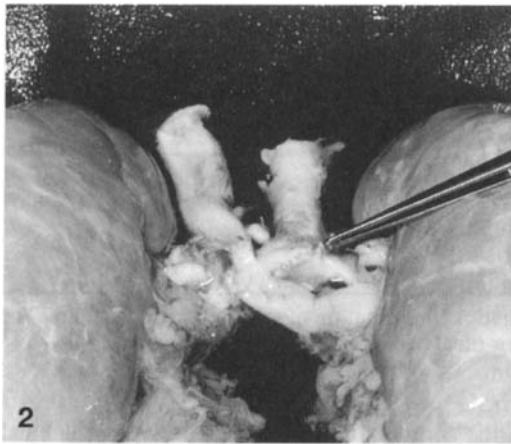
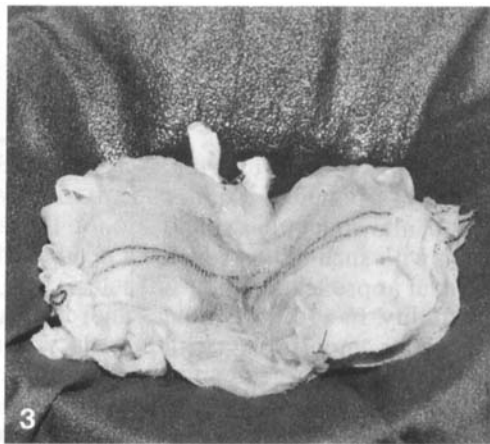
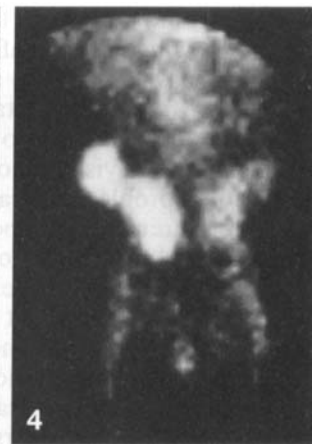Results

To date, a total of seven such "en bloc" renal transplants have been performed in Newcastle. In one case, because of multiple renal arteries to one kidney, a conventional block transplantation was performed, anastomosing the lower aorta and cava and oversewing the top vessels. The results are summarised in Table 1. In no cases were there any technical failures to one or both kidneys of a block. This was confirmed by a DTPA scan in every case. In one case, a retained earlier graft meant that the recipient had a total of five kidneys, including his two native kidneys (Fig. 4).

Unfortunately, in one case, the recipient developed recurrent focal glomerulosclerosis with severe proteinuria, which was her original renal disease. In retro-

Table 1 Outcome of the Newcastle "en bloc" transplants

| Recipient | Donor weight (kg) | Recipient weight (kg) | Donor (months) | Technique | Outcome |
|-----------|-------------------|-----------------------|----------------|--------------|---|
| 1 | 10 | 44 | 14/12 | Newcastle | OK |
| 2 | 10 | 53 | 18/12 | Newcastle | OK |
| 3 | 12 | 60 | 2 years | Newcastle | Uterine Carcinoma |
| 4 | 10.2 | 48 | 2 years | Newcastle | OK |
| 5 | 10 | 49 | 11/12 | Conventional | Recurrent FSGS Focal glomerulosclerosis |
| 6 | 15 | 61 | 25/12 | Newcastle | OK |
| 7 | 11 | 60 | 18/12 | Newcastle | OK |

**Fig. 2** The paediatric block showing the aorta and cava transposition**Fig. 3** The swab "sandwich"**Fig. 4** A DTPA radioisotope study of the Newcastle recipient with an "en bloc" transplant and a retained older transplant in the opposite iliac fossa

spect, perhaps such a transplant was inappropriate for her as early proteinuria is normal with such kidneys [7]. The use of a swab "sandwich" was found to be beneficial because of the propensity for torsion with these transplants. No ureteric complications were seen, and the stents were removed at 6 weeks. One recipient unfortunately died at 1 year post-transplantation from an endometrial tumour.

Discussion

Paediatric donors are clearly underutilised [29]. This is probably due to the low referral rate, which is partly due to the multisystem failure that is often present at the time of a child's death. The other important aspect of using paediatric donors is the continued ignorance as to how best to utilise them. The technical failures seen when transplanting these kidneys either into paediatric or adult recipients have, over the years, prompt-

ed the development of "en bloc" methods that have, in turn, shown that excellent results can, indeed, be obtained [5, 17, 18, 22, 23, 28]. Yet, several groups have persisted with solitary paediatric kidney transplantations into adults and are now also reporting excellent results in double the number of recipients [19, 26, 32]. Such groups reserve paediatric blocks for only the smallest donors (under 1 year) [11] or horseshoe kidneys [30] and, therefore, are shifting the indications. The report of a successful transplant using a 32-week gestational age foetus as a donor for an adult recipient in Oman [3] undoubtedly confirms that "en bloc" transplantation does have a place. The only question that remains is whether to use single or "en bloc" transplantation for a given size donor and recipient. Experience will no doubt eventually solve this problem.

Acknowledgements The authors would like to thank Mike Keir, Consultant in Medical Physics, Royal Victoria Infirmary, for his radioisotope image of the recipient with three renal transplants.

All patients who received these transplants did so with full informed consent. As this technique was not part of a study, ethical committee permission was not sought though the issue was discussed with interested parties.

References

1. Amante AJ, Kahan BD (1996) En bloc transplantation of kidneys from pediatric donors. *J Urol* 155: 852–857
2. Burrows L, Knight R, Polokoff E, Schanzer H, Panico M, Solomon M (1996) Expanding the donor pool with the use of en bloc pediatric kidneys in adult recipients. *Transplant Proc* 28: 173–174
3. Daar A (1996) Transplantation in the middle East and the subcontinent. Presentation to the XVI International Congress of the Transplantation Society. Barcelona 1996
4. Dreikorn K, Rohl L, Horsch R (1977) The use of double renal transplants from paediatric cadaver donors. *Br J Urol* 49: 361–364
5. Gruessner RWG, Matas AJ, Lloveras G, Fryd DS, Dunn DL, Payne WD, Sutherland DER, Najarian JS (1989) A comparison of single and double pediatric cadaver donor kidneys for transplantation. *Clin Transplant* 3: 209–214
6. Hayes JM, Novick AC, Stroom SB, Hodge EE, Bretan PN, Graneto D, Steinmuller DR (1988) The use of single pediatric cadaver kidneys for transplantation. *Transplantation* 45: 106–110
7. Hayes JM, Steinmuller DR, Stroom SB, Novick AC (1991) The development of proteinuria and focal segmental glomerulosclerosis in recipients of pediatric donor kidneys. *Transplantation* 52: 813–817
8. Kirste G, Blumke M, Krumme B (1994) A new operative technique of paratopic positioning of pediatric en bloc kidneys for transplantation. *Clin Transplant* 8: 139–143
9. Kirste G, Waibel B, Krumme B, Pisarski P (1996) Results of en bloc kidney transplantation with a new technique. *Transplant Proc* 28: 420–421
10. Krishnan H, Hannon MF, Bawa SM, Talbot D, Mirza D, Manas D, Thick M (1988) Comparison of the efficacy of University of Wisconsin solution and Newcastle organ perfusion fluid in the preservation of livers for transplantation. *Transpl Int* 11 [Suppl 1]: 387–389
11. Lledo-Garcia E, Moncado-Iribarren I, Escribano-Patino G, Diez-Cordero JM, Luque de Pablos A, Hernandez-Fernandez C (1997) En bloc transplantation of kidneys from pediatric donors. *J Urol* 157: 266–267
12. Luque de Pablos A, Gomez Campdera FJ, Vallejo JL, Rengel MA, Canals MJ, Lopez Gomez JM, Morales D (1984) Transplante renal en bloque en receptores pediatrico. *Nefrology* 4: 161
13. Maranes A, Herrero JA, Marron B, Marques M, Cruceza A, Portoles J, Prats D, Sandrez-Fructuoso AI, Barrientos A (1998) Functional glomerular reserve in recipients of en bloc pediatric transplant kidneys. *Transplantation* 65: 677–680
14. Martins LW, Gonzales LL, West CD, Swartz RA, Sutorius DJ (1969) Homotransplantation of both kidneys from an anencephalic monster to a 17 pound boy with Eagle-Barret syndrome. *Surgery* 66: 603–607
15. Meakins JL, Smith EJ, Alexander JW (1972) En bloc transplantation of both kidneys from pediatric donors into adult patients. *Surgery* 71: 72–75
16. Merkel FK, Matalon TAS (1990) An en bloc method for use of small pediatric cadaver kidneys in adult recipients. *Transplant Proc* 22: 405–406
17. Merkel FK, Matalon TAS, Brunner MC, Patel SK, Siliunas DA (1993) Short- and long-term results with en bloc transplantation of pediatric kidneys into adults. *Transplant Proc* 25: 2167–2169
18. Merkel FK, Miller JL, Ahmad N, Zahid M, Sadiq R, Sodhi B (1997) Transplantation of small pediatric kidneys in adult recipients: a 22-year experience. *Transplant Proc* 29: 2803–2804
19. Modlin CS, Hodge EE, Novick AC (1995) Long term results with single pediatric donor kidney transplants in adult recipients (abstract). *J Urol* (part 2) 153: 529 A
20. Neumayer HH, Huls S, Schreiber M, Riess R, Luft FC (1994) Kidneys from pediatric donors: risk versus benefit. *Clin Nephrol* 41: 94–100
21. Nghiem DD (1991) En bloc transplantation of kidneys from donors weighing less than 15 kg into adult recipients. *J Urol* 145: 14–16
22. Perez-Contin MJ, Mayol J, Gonzalez-Noguera PJ, Grimalt J, Alia J, Rabadan M, Prats D, Torrente J, Fernandez-Represa JA (1995) Reappraisal of transplantation of en-bloc kidneys from very young donors into adult recipients. *Transplantology* 6: 139–141
23. Portoles J, Maranes A, Prats D, Torrente J, Herrero JA, Barrientos A (1995) Kidneys from pediatric donors: is the double implant a solution for adult recipients? *Clin Nephrol* 43: 140
24. Portoles J, Maranes A, Prats D, Torrente J, Marron B, Perez-Contin MJ, Herrero JA, Coronel F, Grimalt J, Barrientos A (1996) Double renal transplant from infant donors. A good alternative for adult recipients. *Transplantation* 61: 37–40
25. Ratner LE, Flye MW (1991) Successful transplantation of cadaveric en-bloc paired pediatric kidneys into adult recipients. *Transplantation* 51: 273–275
26. Ratner LE, Cigarro FG, Bender JS, Magnuson T, Krauss ES (1997) Transplantation of single and paired pediatric kidneys into adult recipients. *J Am Coll Surg* 185: 437–445
27. Satterthwaite R, Aswad S, Sunga V, Shidban H, Mendez RG, Bogaard T, Asai P, Khetan U, Magpayo M, Mendez R (1997) Outcome of en bloc and single kidney transplantation from very young cadaveric donors. *Transplantation* 63: 1405–1410
28. Schneider JR, Sutherland DER, Simmons RL, Fryd DS, Najarian JS (1983) Long-term success with double pediatric cadaver donor renal transplants. *Ann Surg* 197: 439–442
29. Talbot D, Narasimhan KL, Mirza DM, Thick MG, Manas D (1996) More paediatric renal donors should be used for adult recipients. *BMJ* 313: 303
30. Thomson BN, Francis DM, Millar RJ (1997) Transplantation of adult and paediatric horseshoe kidneys. *Aust N Z J Surg* 67: 279–282
31. Trevino G, Dickerman RM, Coggins JT, Greene W, Freeborn W, Vergne-Marini P (1988) The optimal use of pediatric donors for renal transplantation. *Transplant Proc* 20 [Suppl 1]: 359–362
32. Wright F, Banowsky L (1998) Immunosuppressive strategy to increase utilization of donor organs: single pediatric donor kidneys for adult recipients (abstract). World Congress of the Transplant Society, Montreal