

H. P. Lemmens
U. Neumann
W. O. Bechstein
O. Guckelberger
R. Lüsebrink
S. Jonas
H. Keck
P. Neuhaus

Incidence and outcome of arterial complications after orthotopic liver transplantation

H. P. Lemmens (✉) · U. Neumann ·
W. O. Bechstein · O. Guckelberger ·
R. Lüsebrink · S. Jonas · H. Keck ·
P. Neuhaus
Department of Surgery,
Virchow Clinic, Humboldt University,
Augustenburgerplatz 1, D-13353 Berlin,
Germany

Abstract Arterial complications can be a major factor in morbidity and mortality after orthotopic liver transplantation (OLT), as they may cause graft failure, sepsis and complications of the biliary tract. From September 1988 to December 1994, 571 OLT were performed in 529 patients. The follow-up period ranged from 8 to 83 months. Actuarial 1-, 3- and 5-year survival figures were 91 %, 87 % and 85 %, respectively. In 12 cases (2.1 %) complications of the arterial anastomoses were observed. Early arterial complications occurred in eight cases from various causes, while late arterial complications were exclusively

thromboses and developed in four patients 8, 12, 26 and 37 months after surgery, respectively. The main clinical course in patients with arterial thromboses was septic cholangitis with destruction of the biliary tree. Although 70 % of the grafts with arterial thrombosis were lost, 30 % could, at least temporarily, be salvaged by other treatment options. Provided adequate treatment is carried out, arterial complications do not affect overall patient survival.

Key words Liver transplantation · Arterial complications · Hepatic artery thrombosis

Introduction

Arterial complications can be a major factor in morbidity and mortality after orthotopic liver transplantation (OLT), as they may cause graft failure, sepsis and complications of the biliary tract [6, 8, 10, 11]. Early thrombosis of the hepatic artery usually necessitates urgent retransplantation; late occlusions have been successfully treated nonoperatively [4, 7]. Meticulous surgical technique is essential to minimize arterial damage, the need for reconstruction and invisible injuries such as intima lesions. It is important to preserve and to reconstruct, if necessary, accessory hepatic arteries to the graft to ensure adequate arterial perfusion after transplantation [5]. The purpose of this study was to examine the incidence and type of arterial complications, their clinical course, the treatment options and the outcome of patients with arterial complications.

Material and methods

From September 1988 to December 1994, 571 OLT were performed in 529 patients, of whom 519 were adults (98.1 %) and 10 were children less than 16 years of age (1.9 %). Recipient age ranged from 2 to 72 years (median 47 years). The indications for OLT are shown in Table 1. The follow-up period ranged from 8 to 83 months (median 37 months). During donor hepatectomy the coeliac axis was taken including an aortic patch. Accessory arteries were preserved. For eventual vascular reconstruction, the iliac vessels (artery and vein) were also routinely taken. OLT was performed according to standard techniques with the routine use of a venovenous bypass. The arterial anastomosis was generally prepared with a 7/0 prolene running suture using a microsurgical technique. Vascular anastomoses were completed before reperfusion of the graft. Intraoperatively and for 3 days postoperatively, aprotinin 100 000 U/h was used for prevention of hyperfibrinolysis. Heparin treatment started 48 h after OLT with a dosage of 7500–10 000 units per day and was continued until postoperative day 28. In cases of arterial reconstruction of the graft, heparin treatment started 24 h postoperatively at a dose between 7500 and 15 000

units per day, and was also continued until day 28. In the perioperative period fresh frozen plasma and AT III were administered in an attempt to correct coagulation abnormalities.

Dicumarol or aspirin were not given for prevention of arterial thrombosis. The patency of the arterial anastomosis was examined during the first 2 weeks daily by duplex ultrasonography, then during the first postoperative year routinely every 3 months and afterwards annually. When there was any evidence of graft dysfunction the patency of the arterial blood supply was tested, and if indicated an additional angio-CT-scan and/or angiography were performed.

Results

Variations of arterial anatomy of the graft

While 87.7 % of the transplanted grafts had a regular arterial anatomy, 12.3 % showed variations of the hepatic artery as demonstrated in Table 2. All accessory right hepatic arteries (4.6 %) were reconstructed on back table by end-to-end anastomosis to the origin of the donor gastroduodenal or splenic artery.

Locations of the arterial anastomoses

At transplantation in 74.3 % of the cases an end-to-side anastomosis between the coeliac axis of the graft and the common hepatic artery of the recipient at the origin of the gastroduodenal (62.7 %) or splenic artery (11.6 %) was chosen. The different locations of the arterial anastomoses are shown in Table 3.

Early complications

Five adult patients (1.0 %) developed arterial thrombosis in the early postoperative phase, one patient 2 weeks, two patients 6 weeks, one patient 8 weeks and one patient 10 weeks after OLT. The clinical course in four patients was associated with fever and septic cholangitis. One patient developed a fulminant graft failure due to early arterial thrombosis and was successfully treated by an urgent retransplantation (re-OLT). At 28 months he was well with normal liver function. Two of the patients with septic cholangitis were treated by early retransplantation. One of these patients had to be retransplanted again 3 months later due to an intractable chronic rejection. At 31 months, he was in good health with normal liver function. The other retransplanted patient died 12 months later due to fulminant sepsis based on ascendent cholangitis. Upon autopsy arterial thrombosis was excluded. One patient with symptoms of septic cholangitis due to destruction of the biliary system mainly of the left liver lobe was treated successfully with a hepaticojejunostomy. At 32 months the liver function was undisturbed with normal serum bilirubin

Table 1 Indications for liver transplantation

	<i>n</i>	%
Postnecrotic cirrhosis	325	56.8
Cholestatic disease	86	15.1
Liver tumour	38	6.6
Acute liver failure	37	6.5
Metabolic disorder	18	3.2
Other	26	4.6
Retransplantation	41	7.2
Total	571	100

Table 2 Variations in the hepatic arteries of the grafts

	<i>n</i>	%
Normal anatomy	501	87.7
Accessory left hepatic artery	41	7.2
Accessory right hepatic artery	17	3
Accessory left and accessory right hepatic arteries	9	1.6
Others	3	0.5

Table 3 Locations of the arterial anastomoses (recipient) with the donor artery

	<i>n</i>	%
Origin of gastroduodenal artery	358	62.7
Origin of splenic artery	66	11.6
Hepatic artery	54	9.5
Coeliac axis	38	6.7
Common hepatic artery	27	4.7
Suprarenal aorta ^a	14	2.5
Infrarenal aorta ^a	14	2.5
Total	571	100

^a The interposition of a graft (a segment of the donor iliac artery) was necessary for reconstruction in 9/14 and 12/14 cases, respectively

and transaminases. Only the γ GT and the alcalic phosphatase (a. p.) were still elevated (γ GT 400 U/l; use alk. phos. = alkaline phosphatase 800 U/l).

Another patient with early thrombosis of the hepatic artery and destruction of the left biliary tract was treated initially successfully with a temporary PTCO (percutaneous transhepatic cholangio-drainage). At 8 months the bilirubin and the cholestatic enzymes were increasing (bilirubin 4 mg/%; γ GT 400 U/l; use alk. phos. = alkaline phosphatase 700 U/l), so that a re-OLT may be necessary.

A 2-year-old child developed an arterial thrombosis 11 weeks after segment transplantation (segment II and III). The leading clinical symptoms were severe septic cholangitis with fever and increased cholestatic enzymes, so that re-OLT was inevitable. After re-OLT

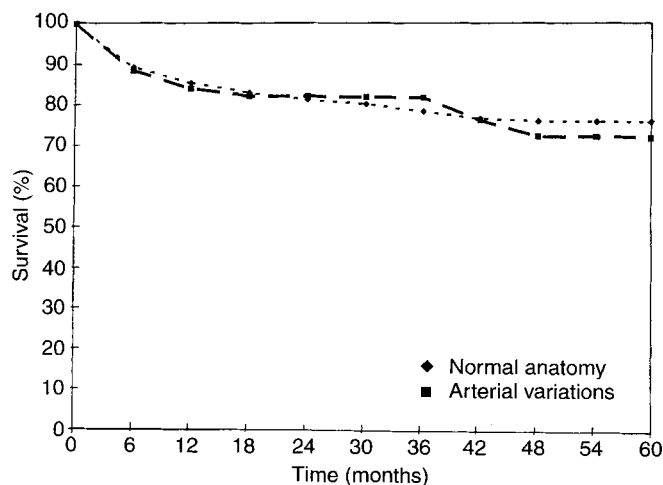


Fig. 1 Graft survival according to the arterial anatomy

(also a segment transplantation) the clinical course was uneventful during a follow-up of up to 13 months.

One patient in our series suffered a severe intraabdominal hemorrhage 6 weeks after OLT caused by a mycotic aneurysm of the hepatic artery at the area of anastomosis. The aneurysm was treated by resection and interposition of a venous graft (vena saphena magna). The follow-up (28 months) was undisturbed.

One patient developed a slight elevation of SGOT (200 U/l) and SGPT (230 U/l) 11 weeks after OLT while bilirubin and the synthetic function of the liver were normal. Rejection and infection were ruled out. On angio-CT-scanning a diminished arterial perfusion was seen without perfusion defects. Simultaneously performed coeliacography showed a 70% stenosis of the arterial anastomosis. As transaminases decreased and liver function was undisturbed, specific treatment was not necessary. This patient was followed up for 38 months.

Late arterial complications

Late arterial complications were exclusively thromboses, and developed in four adult patients 8, 12, 26 and 37 months after surgery, respectively. In two patients septic cholangitis based on an increasing destruction of the biliary system was the leading clinical sign of the arterial thrombosis. These patients were successfully retransplanted with normal liver function until the time of writing (47 and 16 months after re-OLT).

One patient developed a temporary dysfunction of the graft 26 months after OLT due to arterial thrombosis with an elevation of SGOT to 2000 U/l and of bilirubin to 6 mg%. As liver function first normalized, no specific treatment was necessary. During more recent months, however, this patient suffered from increased

cholangitis. Destruction of the biliary tree was found on ERC (endoscopic retrograde cholangiography). With decreasing liver function a re-OLT may be necessary in the near future. The fourth patient developed fulminant graft failure with hepatic coma due to a late arterial thrombosis 12 months after OLT. The liver function at this time was reduced due to a HCV (hepatitis c virus) reinfection. The liver function decreased 9 months after an initially successful re-OLT again due to HCV (hepatitis c virus) reinfection (bilirubin 20 mg/%; PT (prothrombine time) 30 %).

Patient and graft survival

Actuarial 1-, 3- and 5-year patient survival figures of all patients were 91%, 87% and 85%, respectively. Patient survival was not different between patients with or without arterial complications. Of 12 patients with arterial thrombosis, 1 (8.3%) died during the follow-up period. There were also no differences in the survival rates of grafts with or without anatomical variations of the hepatic artery as demonstrated in Fig. 1. Of the 12 patients with arterial complications, 7 (58%) needed re-OLT, while 5 (42%) could be at least temporarily salvaged with other treatment options.

Discussion

The incidence of arterial complications after OLT was a significant prognostic factor in the past [2, 4, 6, 8-11]. However, with refinements in surgical technique, arterial complications have become a rare event and have no influence on mortality of the patients. An arterial thrombosis after liver transplantation is usually considered as an indication for urgent retransplantation [10, 11]. Although in our series 3 out of 10 patients with hepatic artery thrombosis could be treated successfully at least temporarily with other options, during follow-up in two patients increased biliary destruction gradually developed. An alternative procedure for the treatment of arterial thrombosis instead of retransplantation can be an urgent revascularization [7, 12]. Recently successful angiographic revascularizations of hepatic artery thromboses after OLT have been described [1, 3].

Prompt surgical revascularization or retransplantation is still the cornerstone of treatment of most cases of hepatic artery thrombosis following OLT to avoid destruction of the biliary tree and septic complications.

References

1. Bjerkvik PS, Vatne K, Mathisen O, Sorlide O (1995) Percutaneous revascularization of postoperative hepatic artery thrombosis in a liver transplant. *Transplantation* 59: 1746–1748
2. Blumhardt G, Ringe B, Lauchart W, Burdelski M, Bechstein WO, Pichlmayr R (1987) Vascular problems in liver transplantation. *Transplant Proc* 19: 2412
3. Figueras J, Busquets J, Dominguez J, Sancho C, Casanovas-Taltavull T, Rafeecas A, Fabregat J, Torras J, Jaurrieta E (1995) Intraarterial thrombolysis in the treatment of acute hepatic artery thrombosis after liver transplantation. *Transplantation* 59: 1356–1357
4. Langnas A, Marujo W, Stratta R, Wood R, Shaw B (1991) Vascular complications after orthotopic liver transplantation. *Am J Surg* 161: 76–83
5. Lemmens HP, Blumhardt G, Neuhaus P, Keck H, Tsiblaskis N, Rossaint R, Langer R, Steffen R (1992) Technique of arterial anastomosis in liver transplantation, surgical management in routine situations and anatomical variations. *Transplant Int* 5: 198
6. Lerut J, Gordon R, Iwatsuki S, Starzl TE (1987) Surgical complications in human orthotopic liver transplantation. *Acta Chir Belg* 87: 193–204
7. Marujo WC, Langnas AN, Wood R, Stratta R, Li S, Shaw B (1991) Vascular complications following orthotopic liver transplantation: outcome and the role of urgent revascularization. *Transplant Proc* 23: 1484–1486
8. Starzl TE, Demetris A, van Thiel D (1989) Liver transplantation. *N Engl J Med* 321: 1092–1099
9. Todo S, Makowa L, Tzakis A, Marsh J, Karrer FM, Armany M, Miller C, Teller M, Esquivel C, Gordon R (1987) Hepatic artery in liver transplantation. *Transplant Proc* 19: 2406–2411
10. Tzakis A (1985) The dearterialized liver graft. *Semin Liver Dis* 5: 375–376
11. Tzakis A, Gordon R, Shaw B, Iwatsuki S, Starzl TE (1985) Clinical presentation of hepatic artery thrombosis after liver transplantation in the cyclosporine era. *Transplantation* 40: 667–671
12. Yanaga K, Lebeau G, Marsh J, Gordon R, Makowa L, Tzakis A, Todo S, Stieber A, Iwatsuki S, Starzl TE (1990) Hepatic artery reconstruction for hepatic artery thrombosis after orthotopic liver transplantation. *Arch Surg* 125: 628–631